

Acta Medica Okayama

Volume 43, Issue 3

1989

Article 7

JUNE 1989

Elevated IgA antibodies to Epstein-Barr virus in children with chronic active Epstein-Barr virus infection.

Hiroshi Wakiguchi*

Mikiya Fujieda†

Haruo Kubota‡

Kenji Matsumoto**

Akiko Wakiguchi††

Takanobu Kurashige‡‡

Megumi Oda§

*Kochi Medical School,

†Kochi Medical School,

‡Kochi Medical School,

**Kochi Medical School,

††Kochi Medical School,

‡‡Kochi Medical School,

§Okayama University,

Elevated IgA antibodies to Epstein-Barr virus in children with chronic active Epstein-Barr virus infection.*

Hiroshi Wakiguchi, Mikiya Fujieda, Haruo Kubota, Kenji Matsumoto, Akiko Wakiguchi, Takanobu Kurashige, and Megumi Oda

Abstract

Anti-Epstein-Barr virus (EBV) antibodies were tested in 11 children with chronic active EBV infection. Anti-virus capsid antigen (VCA)-IgG antibody titers ranged from 1:640 to 1:10,240. Anti-VCA-IgM antibody was consistently positive in 5 of the 11 patients; anti-VCA-IgA antibody was consistently positive in 6 of the 10 patients; anti-early antigen (EA)-IgG antibody was consistently positive in 10 of the 11 patients and anti-EA-IgA antibody was consistently positive in 4 out of the 7 patients. Anti-EBV nuclear antigen (EBNA) antibody was not detected in two patients. Consistently positive anti-VCA-IgA- and anti-EA-IgA- antibody may be a characteristic feature of abnormal antibody responses in severe chronic active EBV-infection in childhood.

KEYWORDS: IgA antibody, Epstein-Barr virus, chronic active EBV-infection

*PMID: 2548373 [PubMed - indexed for MEDLINE]

Copyright (C) OKAYAMA UNIVERSITY MEDICAL SCHOOL

Elevated IgA Antibodies to Epstein-Barr Virus in Children with Chronic Active Epstein-Barr Virus Infection

Hiroshi Wakiguchi*, Mikiya Fujieda, Haruo Kubota, Kenji Matsumoto, Akiko Wakiguchi, Takanobu Kurashige and Megumi Oda^a

Department of Pediatrics, Kochi Medical School, Nankoku, Kochi 781-51 and ^aDepartment of Pediatrics, Okayama University Medical School, Okayama 700, Japan

Anti-Epstein-Barr virus (EBV) antibodies were tested in 11 children with chronic active EBV infection. Anti-virus capsid antigen (VCA)-IgG antibody titers ranged from 1:640 to 1:10,240. Anti-VCA-IgM antibody was consistently positive in 5 of the 11 patients; anti-VCA-IgA antibody was consistently positive in 6 of the 10 patients; anti-early antigen (EA)-IgG antibody was consistently positive in 10 of the 11 patients and anti-EA-IgA antibody was consistently positive in 4 out of the 7 patients. Anti-EBV nuclear antigen (EBNA) antibody was not detected in two patients. Consistently positive anti-VCA-IgA- and anti-EA-IgA- antibody may be a characteristic feature of abnormal antibody responses in severe chronic active EBV-infection in childhood.

Key words : IgA antibody, Epstein-Barr virus, chronic active EBV-infection

It is well known that elevated IgA antibody against virus capsid antigen (VCA) of Epstein-Barr (EB) virus is one of the characteristic features of nasopharyngeal carcinoma. VCA-IgA antibody may also be transiently detectable in the course of acute infectious mononucleosis (1). EB-virus infection may become a chronic active state in both adults and children. Several immunological abnormalities such as defective natural killer (NK) cell activity, EB-virus specific cytotoxic T lymphocyte (CTL) activity, and lymphokine production have been reported in patients with chronic active EB-virus infection (3-6). Akaboshi *et al.*

(2) noted that elevated IgA antibodies to EB-virus were found in children with recurrent parotitis caused by EB-virus. Though a few VCA-IgA antibody positive cases of chronic active EB-virus infection have been described (7-9), only little research had been done on the significance of IgA antibodies to EB-virus in chronic active EB-virus infection.

We examined EB-virus antibodies specifically IgA antibodies to EB-virus in 11 children and infants with chronic active EB-virus infection. The diagnostic criteria (10) for chronic active EB-virus infection are; 1) chronic or recurrent infectious mononucleosis-like symptoms lasting for a period of at least one year and often longer,

*To whom correspondence should be addressed.

Table 1 Clinical data of patients with chronic active Epstein-Barr virus infection

Case	Sex	Age at onset (y-m)	Liver (cm) ^a	Spleen (cm) ^a	Lymphnode (cm) ^b	Rash	Fever	Complications and clinical course
1. M. M.	M	0- 1	6.5	6.0	2.0	+	+	Pneumonitis, remission at 12 m after onset
2. Y. C.	M	0- 3	5.0	9.0	3.0	+	+	Pneumonitis, active more than 4 y after onset
3. K. I.	M	12- 0	4.0	15.0	2.0	-	+	NHL, dead at 13m after onset
4. K. K.	M	8- 5	1.5	0.5	0.5	-	-	Hemolytic anemia, active more than 3 y after onset
5. M. S.	M	2- 6	7.0	12.0	7.0	+	+	HD, dead at 6 y after onset
6. R. F.	M	2- 4	5.0	9.0	2.5	+	-	Hemolytic anemia, active more than 2 y after onset
7. F. A.	F	7- 6	1.0	5.0	0.5	+	+	Chronic hepatitis, active more than 2 y after onset
8. M. I.	F	5-11	0	0	0.5	+	+	Fever and arthritis, active more than 4 y after onset
9. M. W.	F	12- 1	10.0	12.0	2.0	-	+	VAHS, CMV-pneumonitis, dead at 26 m after onset
10. R. O.	M	10- 0	3.0	1.0	1.0	+	-	Chronic active hepatitis, active more than 14 m after onset
11. Y. S.	M	11- 0	9.0	6.0	2.0	-	+	VAHS, dead at 2 m after onset

a: Length below costal margin.

b: Size in diameter.

Abbreviations: y, year(s); m, month(s); NHL, non Hodgkin's lymphoma; HD, Hodgkin's disease; VAHS, virus associated hemophagocytic syndrome; CMV, cytomegalovirus.

2) an unusual pattern of anti-EB-virus antibodies with raised anti-early antigen (EA) and/or absent anti-EB-virus nuclear antigen (EBNA) titers, and 3) no evidence of any prior immunological abnormality or of any other recent infection by which to explain the condition.

The patients characteristically had a lymphoproliferative syndrome similar to Duncan disease (X-linked lymphoproliferative syndrome, XLP), however no familial involvement was observed and the disease occurred in both males and females (Table 1). The age of the patients at onset varied from one month to 12 years. None of the patients had characteristic symptoms of acute infectious mononucleosis in their past history. One patient entered into remission 12 months after onset of the disease, two patients died

from malignant lymphoma and two patients died from virus associated hemophagocytic syndrome and cytomegalovirus pneumonitis (Table 1).

All serum samples were obtained during the active state of the disease and some of them were frozen and stored at -80°C for 1 to 2 years before anti-EB-virus antibodies were tested. Anti-VCA-antibodies and anti-EA-antibodies were tested by an indirect immunofluorescence technique (11, 12), and anti-EBNA-antibody was tested by an indirect immunofluorescence with complement method (13).

At the time when the patients were diagnosed as suffering from chronic active EB-virus infection, anti-EB-virus antibody titers were as follows. High titers of anti-VCA-IgG antibodies were detectable in all cases

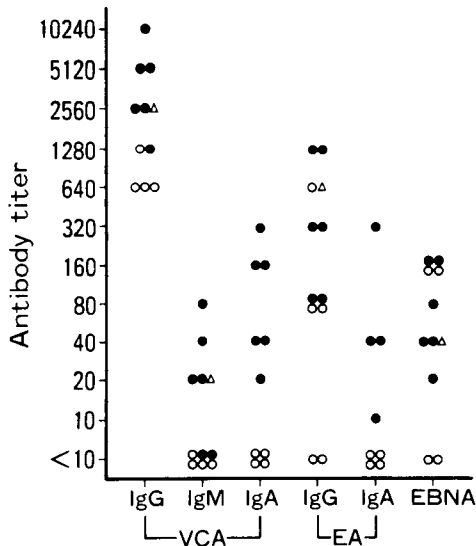


Fig. 1 Anti-Epstein-Barr virus antibodies in patients with chronic active Epstein-Barr virus infection. Anti-virus capsid antigen antibodies (VCA), anti-early antigen antibodies (EA) and anti-nuclear antigen antibody (EBNA) were tested. VCA-IgA antibody positive cases are expressed by filled circles, VCA-IgA antibody negative cases are expressed by open circles, and a case whose VCA-IgA antibody was not tested is expressed by triangles.

(1:640 to 1:10,240), anti-VCA-IgM antibody was detectable in 5 cases (1:20 to 1:80), anti-EA-IgG antibody was positive in 10 cases (1:80 to 1:1,280) and anti-EBNA antibody was lower than 1:10 in 2 cases (Fig. 1). Anti-VCA-IgA antibody was positive (1:20 to 1:320) in 6 out of 10 cases tested, and anti-EA-IgA antibody was positive (1:10 to 1:320) in 4 out of 7 cases tested. Anti-VCA-IgA and anti-EA-IgA antibody positive cases showed higher anti-VCA-IgG and anti-VCA-IgM antibodies than IgA antibody negative cases indicating elevated antibody production had occurred in IgA antibody positive cases. Anti-VCA-IgA antibody and anti-EA-IgA antibody were consistently detectable in IgA-antibody positive cases during the period of observation (12 to 36 months).

Some of the anti-EB-virus IgA antibody positive cases, reported by Akaboshi *et al.* (2), might be clinically diagnosed as chronic active EB-virus infection. IgA antibodies to EB-virus are not detectable in normal EB-virus seropositive individuals and are transiently detectable during the course of acute infectious mononucleosis (1). Tosato *et al.* (14) described the immunological state of chronic active EB-virus infection appear "frozen" in a state typically found only briefly during the convalescence from acute EB-virus infection. Consistently positive IgA antibodies to EB-virus may indicate that an active stage of EB-virus infection as high as in the acute stage of acute infectious mononucleosis persists in patients with chronic active EB-virus infection. Three out of 6 IgA antibody positive cases died from malignant lymphoma and virus associated hemophagocytic syndrome with pneumonitis, while all 4 IgA-antibody negative cases are still alive, one of them in complete remission. We would like to emphasize that the elevated IgA antibodies to EB-virus is probably a characteristic immunological abnormality in severe types of chronic active EB-virus infection.

Acknowledgments. The authors thank Mr. Conrad Zagory, Jr. for his help with the manuscript, and Miss Michiyo Mori for typing the manuscript.

References

1. Henle G and Henle W: Epstein-Barr virus-specific IgA serum antibodies as an outstanding feature of nasopharyngeal carcinoma. *Int J Cancer* (1976) 17, 1-7.
2. Akaboshi I, Katsuki T, Yamamoto J and Matsuda I: Unique pattern of Epstein-Barr virus specific antibodies in recurrent parotitis. *Lancet* (1983) 2, 1049-1051.
3. Kibler R, Lucas DO, Hicks MJ, Poulos BT and Jones JF: Immune function in chronic active Epstein-Barr virus infection. *J Clin Immunol* (1985) 5, 46-54.
4. Masucci MG, Szigeti R, Ernberg I, Masucci G,

- Chessels J, Sielt C, Lie S, Glomstein A, Busincol L, Henle W, Henle G, Pearson G, Sakamoto K and Purtilo DT: Cellular immune defects to Epstein-Barr virus-induced antigens in young males. *Cancer Res* (1981) **41**, 4284-4291.
5. Wakiguchi H, Fujieda M, Matsumoto K, Ohara Y, Wakiguchi A and Kurashige T: Defective killer cell activity in patients with chronic active Epstein-Barr virus infection. *Acta Med Okayama* (1988) **42**, 137-142.
6. Virelizier J-L, Lenoir G and Griscelli C: Persistent Epstein-Barr virus infection in a child with hypergammaglobulinemia and immunoblastic proliferation associated with a selective defect in immune interferon secretion. *Lancet* (1978) **2**, 231-234.
7. Kuis W, Rood JJ, Zegers BJM, Rickinson AB, Kapsenberg JG, The H and Stoop JW: Heterogeneity of immune defects in three children with a chronic active Epstein-Barr virus infection. *J Clin Immunol* (1985) **5**, 377-385.
8. Henle W, Henle G, Andersson J, Ernberg I, Klein G, Horwitz CA, Marklund G, Rymo L, Wellinder C and Straus SE: Antibody responses to Epstein-Barr virus-determined nuclear antigen (EBNA)-1 and EBNA-2 in acute and chronic Epstein-Barr virus infection. *Proc Natl Acad Sci USA* (1987) **84**, 570-574.
9. Schooley RT, Carey RW, Miller G, Henle W, Eastman R, Mark EJ, Kenyon K, Wheeler EO and Rubin RH: Chronic Epstein-Barr virus infection associated with fever and interstitial pneumonitis. *Ann Intern Med* (1986) **104**, 636-643.
10. Rickinson AB: Chronic, symptomatic Epstein-Barr virus infection. *Immunol Today* (1986) **7**, 13-14.
11. Henle G and Henle W: Immunofluorescence in cells derived from Burkitt's lymphoma. *J Bacteriol* (1966) **91**, 1248-1256.
12. Henle W, Henle G, Zajac BA, Pearson G, Waubke R and Scriba M: Differential reactivity of human serum with early antigens induced by Epstein-Barr virus? *Science* (1970) **169**, 188-190.
13. Reedman BM and Kelen G: Cellular localization of an Epstein-Barr virus (EBV)-associated complement-fixing antigen in producer and non-producer lymphoblastoid cell lines. *Int J Cancer* (1974) **13**, 751-754.
14. Tosato G, Straus S, Henle W, Pike SE and Blaese RM: Characteristic T cell dysfunction in patients with chronic active Epstein-Barr virus infection (chronic infectious mononucleosis). *J Immunol* (1985) **134**, 3082-3088.

Received December 5, 1988 ; accepted March 7, 1989