

Acta Medica Okayama

Volume 52, Issue 6

1998

Article 6

DECEMBER 1998

Results of surgical treatment for ossification of the posterior longitudinal ligament of the thoracic spine.

Masuo Senda*

Yoshiaki Harada†

Kazuhiro Takeuchi‡

Sinnosuke Nakahara**

Hajime Inoue††

*Okayama University,

†Okayama University,

‡Okayama University,

**Okayama National Hospital,

††Okayama University,

Results of surgical treatment for ossification of the posterior longitudinal ligament of the thoracic spine.*

Masuo Senda, Yoshiaki Harada, Kazuhiro Takeuchi, Sinnosuke Nakahara, and Hajime Inoue

Abstract

Conservative treatment is ineffective for ossification of the posterior longitudinal ligament (OPLL) in the thoracic spine, and surgical treatment is indicated for most cases, while such cases are not often experienced. In the present study, the results of surgical management involving mainly posterior decompression for this disease were evaluated clinically. The study included 9 patients (1 man and 8 women) who underwent surgical treatment for OPLL of the thoracic spine between 1984 and 1993. Laminectomy was performed in 5 patients, and laminectomy plus anterior decompression of the OPLL via the posterior approach based on Otsuka's method was performed in 2 patients. In 1 patient, laminoplasty for OPLL of the cervical spine was combined with laminectomy of the symptomatic lesion in the thoracic spine. One patient underwent anterior decompression and fusion. The results were evaluated using the Japanese Orthopaedic Association score (JOA score) and recovery rate. The postoperative follow-up period ranged from 1 year to 10 years and 3 months (mean, 4 years and 6 months). The mean JOA score was 4.8 before surgery and improved to 7.6 at the final examination. This was a mean recovery rate of 50.1%. Symptoms caused by OPLL in the thoracic spine can be alleviated by posterior decompression where OPLL extends from the upper to the middle thoracic spine or extends from the middle to the lower thoracic spine. It seems, however, that OPLL localized to the middle thoracic spine requires anterior decompression.

KEYWORDS: ossification of the posterior longitudinal ligament, thoracic spine, surgical treatment

*PMID: 9876769 [PubMed - indexed for MEDLINE]

Copyright (C) OKAYAMA UNIVERSITY MEDICAL SCHOOL

Results of Surgical Treatment for Ossification of the Posterior Longitudinal Ligament of the Thoracic Spine

Masuo SENDA^{a*}, Yoshiaki HARADA^a, Kazuhiro TAKEUCHI^a, Sinnosuke NAKAHARA^b and Hajime INOUE^a

^aDepartment of Orthopaedic Surgery, Okayama University Medical School, Okayama 700-8558 and ^bDepartment of Orthopaedic Surgery, Okayama National Hospital, Okayama 700-8566, Japan

Conservative treatment is ineffective for ossification of the posterior longitudinal ligament (OPLL) in the thoracic spine, and surgical treatment is indicated for most cases, while such cases are not often experienced. In the present study, the results of surgical management involving mainly posterior decompression for this disease were evaluated clinically. The study included 9 patients (1 man and 8 women) who underwent surgical treatment for OPLL of the thoracic spine between 1984 and 1993. Laminectomy was performed in 5 patients, and laminectomy plus anterior decompression of the OPLL via the posterior approach based on Ohtsuka's method was performed in 2 patients. In 1 patient, laminoplasty for OPLL of the cervical spine was combined with laminectomy of the symptomatic lesion in the thoracic spine. One patient underwent anterior decompression and fusion. The results were evaluated using the Japanese Orthopaedic Association score (JOA score) and recovery rate. The postoperative follow-up period ranged from 1 year to 10 years and 3 months (mean, 4 years and 6 months). The mean JOA score was 4.8 before surgery and improved to 7.6 at the final examination. This was a mean recovery rate of 50.1%. Symptoms caused by OPLL in the thoracic spine can be alleviated by posterior decompression where OPLL extends from the upper to the middle thoracic spine or extends from the middle to the lower thoracic spine. It seems, however, that OPLL localized to the middle thoracic spine requires anterior decompression.

Key words: ossification of the posterior longitudinal ligament, thoracic spine, surgical treatment

Conservative treatment is rarely effective for ossification of the posterior longitudinal ligament (OPLL) of the thoracic spine, and surgical treatment is performed for most cases. However, surgical treatment for OPLL of the thoracic spine has been less successful than surgical treatment for OPLL of the cervical spine, and the choice of a surgical approach is controversial for this condition. In this study, the results of surgical management involving mainly posterior decompression were evaluated clinically, and the surgical interventions are discussed.

Patients and Methods

The study included 9 patients (1 man and 8 women) who underwent surgical treatment for OPLL of the thoracic spine between 1984 and 1993. The mean age at the time of surgery was 55 years (range: 33-74 years). The postoperative follow-up period ranged from 1 year to 10 years and 3 months (mean, 4 years and 6 months). OPLL was localized to the upper thoracic spine in 2 patients and to the middle thoracic spine in 2 patients. OPLL extended from the upper to middle thoracic spine in 1 patient, from the upper thoracic to lower thoracic spine in 2 patients, and from the middle to lower thoracic spine in 2 patients. OPLL was combined with ossification of the yellow ligament (OYL) in 5 patients.

Laminectomy was performed in 5 patients, and laminectomy plus anterior decompression of the OPLL via the posterior approach based on Ohtsuka's method (1) was performed in 2 patients. In 1 patient, laminoplasty for OPLL of the cervical spine was performed in addition to laminectomy of the symptomatic lesion in the thoracic spine. One patient underwent anterior decompression and

* To whom correspondence should be addressed.

Table 1 Evaluation system for thoracic myelopathy: Japanese Orthopaedic Association (JOA) score and recovery rate^a

Category		Score
A. Lower extremity motor function	Unable to stand up and walk by any means	0
	Unable to walk without a cane or other support on the level	1
	Walks independently on the level but needs support on stairs	2
	Capable of fast walking but clumsy	3
	Normal	4
B. Sensory function		
I. Lower extremity	Apparent sensory loss	0
	Minimal sensory loss	1
	Normal	2
II. Trunk	Apparent sensory loss	0
	Minimal sensory loss	1
	Normal	2
C. Bladder function	Urinary retention and/or incontinence	0
	Sense of retention and/or dribbling and/or thin stream	1
	Urinary retardation and/or pollakiuria	2
	Normal	3
Total for normal patient		11

$$a : \text{Recovery rate (\%)} = \frac{\text{postoperative score} - \text{preoperative score}}{11 - \text{preoperative score}} \times 100.$$

fusion.

The results were evaluated using the Japanese Orthopaedic Association (JOA) score after excluding upper limb items, so that a maximum score was 11 points. The recovery rate was calculated from the scores (Table 1).

Results

Patients Nos. 1 and 2 had OPLL localized to the upper thoracic spine, patient No. 3 had OPLL extending from the upper to the middle thoracic spine, patients Nos. 4 and 5 had OPLL extending from the upper to lower thoracic spine, patients Nos. 6 and 7 had OPLL localized to the middle thoracic spine, and patients Nos. 8 and 9 had OPLL extending from the middle to lower thoracic spine (Table 2). No patient showed disease progression after surgical treatment according to the JOA score, although no improvement was observed in patient No. 5. In patient No. 2 (OPLL localized to the upper thoracic spine) and No. 3 (OPLL localized from the upper to the middle thoracic spine), the recovery rate was 57.1% and 80.0%, respectively. In patients Nos. 8 and 9 (OPLL of the middle and lower thoracic spine), the recovery rate was 100%. On the whole, the mean JOA score was 4.8 before surgery and improved to 7.6 at the final examination. This was a mean recovery rate of 50.1% (Table 2).

Typical cases in our series are presented below:

Patient No. 6: A 61-year-old woman had OPLL at T5-T7 and OYL at T6-T11. Laminectomy via the posterior approach and anterior decompression based on Ostuka's method was performed. Postoperative CT showed some residual OPLL, but it was considered that adequate decompression of the spinal cord had been achieved. The preoperative JOA score was 3 and it improved to 6. The improvement rate was 37.5% (Fig. 1).

Patient No. 9: A 56-year-old woman had OPLL at T7-T11, and OYL at T11-T12. Laminectomy was performed at the T7-T12 level. The preoperative JOA score was 9 and this improved to 11 at the final examination. The improvement rate was 100%. In this case, OYL combined with the OPLL was considered to play a considerable role in the symptoms (Fig. 2).

Discussion

Selection of the best operative approach for OPLL of the thoracic spine is still controversial and no standard method has been established. Fujimura *et al.* (2) reported the results of anterior decompression and fusion via the extrapleural approach in the treatment of thoracic myelopathy secondary to OPLL in 33 cases. They re-

Table 2 Results of surgical treatment of 9 patients with OPLL of the thoracic spine

Case	Age (years)	Sex	Site of ossification	Myelography	OYL	Surgical approach	Follow-up period	JOA score	Recovery rate
1	67	F	T1-T3	T1/2	(-)	Laminectomy at C7-T3	7y 5m	5→7	33.3
2	74	F	T2-T4	T2/3	(-)	Laminectomy at T1-T4 and anterior decompression via posterior at T2/3 and T3/4	4y 6m	4→8	57.1
3	44	F	T4-T8	T4/5	(+) T10-12	Laminectomy at T3-T11	3y 7m	6→10	80.0
4	33	M	T1-T12	T3/4	(+) T2-4	Laminectomy at T1-T7	10y 3m	4→6	28.6
5	61	F	T4-L1	T10/11	(-)	Laminectomy at T8-T12	2y 7m	4→4	0
6	61	F	T5-T7	T6/7	(+) T6-11	Laminectomy at T4-T8 and anterior decompression via posterior at T4-T8	1y	3→6	37.5
7	47	F	T5-T7	T5/6	(-)	Anterior decompression via anterior at T5-T7	1y 1m	4→5	14.5
8	52	F	T6-T12 (C3-C6)	T11/12	(+) T11/12	Laminectomy at T10-T12 Laminoplasty at C3-T1	4y	4→11	100.0
9	56	F	T7-T12	T11/12	(+) T11/12	Laminectomy at T7-T12	1y	9→11	100.0

OPLL: Ossification of the posterior longitudinal ligament; OYL: Ossification of the yellow ligament; JOA: Japanese Orthopaedic Association; y: Year; m: Month.

Recovery rate: See legend to Table 1. "Myelography" means the site of a complete block on myelography.

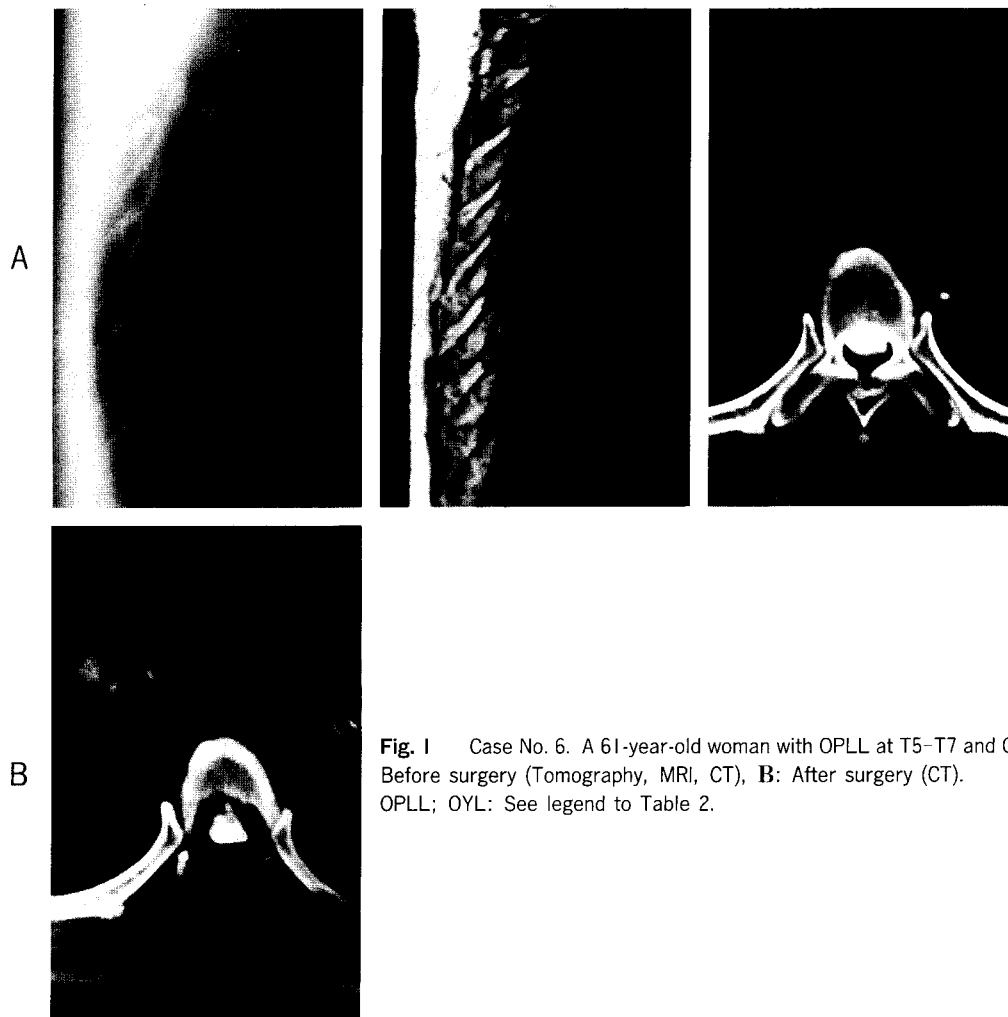


Fig. 1 Case No. 6. A 61-year-old woman with OPLL at T5-T7 and OYL at T6-T11. **A:** Before surgery (Tomography, MRI, CT), **B:** After surgery (CT). OPLL; OYL: See legend to Table 2.

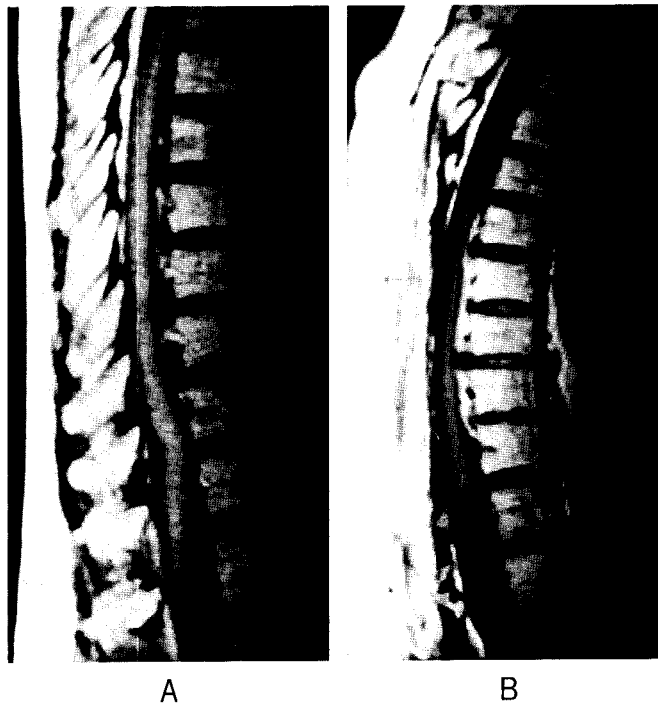


Fig. 2 Case No. 9. A 56-year-old woman with OPLL at T7-T11 and OYL at T11-T12. **A:** Before surgery (T1 weighted MRI), **B:** After surgery (T1 weighted MRI).
OPLL; OYL: See legend to Table 2.

ported that the average recovery rate was 53.2%, however, postoperative complications included 3 cases of deterioration of thoracic myelopathy and 4 cases of extrapleural cerebrospinal fluid leakage. Ido *et al.* (3) reported the results of anterior decompression and fusion for OPLL in 12 patients. They reported that the clinical symptoms were alleviated and JOA scores were recovered in 10 of the cases but were unchanged in 2, and complications of cerebrospinal fluid (CSF) leakage, CSF fistula and the recurrent laryngeal nerve paralysis were noted. Tomita *et al.* (4) reported the circumference of spinal cord decompression for thoracic myelopathy due to combined ossification of OPLL and OYL in 12 patients. Their operation consisted of 2 steps; posterior and lateral decompression of the spinal cord by removal of the OYL, and anterior decompression by thoracotomy. They commented that their operation was not easy, but it was a radical and promising surgical procedure. Katoh *et al.* (5) recommended that anterior decompression via the posterior approach should be applied when preoperative lower limb function had a score of 1 or less, or even in patients with a score of 2 or more when OPLL was localized to

3 or 4 vertebral bodies. They recommended posterior decompression in patients with score of 2 or more when OPLL extended over 5-6 vertebral bodies. Kurosa *et al.* (6) reported that posterior decompression, as well as anterior decompression, is effective in the first pattern (OPLL localized to the central part of S-curve) in the cervicothoracic region and in the second pattern (OPLL localized just above apical vertebra). In the third pattern (OPLL combined with OYL below apical vertebra), they reported that transthoracic anterior decompression surgery was the best method for most patients. Muramoto *et al.* (7) reported that they did not achieve satisfactory results with anterior decompression via the posterior approach. Tsuzuki *et al.* (8) reported extensive cervicothoracic laminoplasty decompression for OPLL. They noted that the average JOA score was 4.3 before surgery and 9.1 postoperatively. They recommended their laminoplasty posterior decompression.

In this study, the mean recovery rate was 50.1% and this rate was almost the same as the recovery rate reported by Fujimura *et al.* (2). In the patients with OPLL extending from the upper to the middle thoracic

spine or OPLL extending from the middle to the lower thoracic spine (Cases No. 1, 2, 3, 8, 9), the mean recovery rate was 74.1%. However, in the patients with OPLL extending from the upper to the lower thoracic spine or OPLL localized to the middle thoracic spine (Cases No. 4, 5, 6, 7), the mean recovery rate was 20.5%. These results show that posterior decompression was effective for OPLL extending from the upper to middle thoracic spine or OPLL extending from the middle to the lower thoracic spine. On the other hand, in the patients with OPLL combined with OYL (Cases No. 3, 4, 6, 8, 9), the mean recovery rate was 69.2%. Posterior decompression for OPLL combined OYL was relatively effective for OPLL combined with OYL.

OPLL is an anterior lesion, so anterior decompression is theoretically appropriate, but this is associated with considerable surgical stress, postoperative complications and technical difficulties. The results obtained in the present study suggest that symptoms can be improved by posterior decompression when OPLL extends from the upper to the middle thoracic spine or extends from the middle to the lower thoracic spine. It seems, however, that OPLL localized to the middle thoracic spine requires anterior decompression.

References

1. Ohtsuka K, Terayama K, Tsuchiya T, Wada K, Furukawa K and

- Ohkubo M: A surgical procedure for the anterior decompression of thoracic spinal cord through the posterior approach. *Orthop Surg Traumatol* (1983) **26**, 1083-1090 (in Japanese).
2. Fujimura Y, Nishi Y, Nakamura M, Toyama Y and Suzuki N: Long-term follow-up study of anterior decompression and fusion for thoracic myelopathy resulting from ossification of the posterior longitudinal ligament. *Spine* (1997) **22**, 305-311.
3. Ido K, Shimizu Y, Nakayama Y, Yamamuro T, Shikata J, Matsushita M and Nakamura T: Anterior decompression and fusion for ossification of posterior longitudinal ligament in the thoracic spine. *J Spinal Disord* (1995) **8**, 317-323.
4. Tomita K, Kawahara N, Baba H, Kikuchi Y and Nishimura H: Circumspinal decompression for thoracic myelopathy due to combined ossification of the posterior longitudinal ligament and ligamentum flavum. *Spine* (1990) **15**, 1114-1120.
5. Katoh D, Gotoh S, Murakami M, Kita T, Ookawa A, Konno S, Motegi H, Moriya H and Mochizuki M: Selecting a surgical method for ossification of longitudinal ligament in the thoracic spine. *J Jpn Orthop Assoc* (1994) **68**, S498 (in Japanese).
6. Kurosa Y, Yamaura I, Nakai O and Shinomiya K: Selecting a surgical method for thoracic myelopathy caused by ossification of the posterior longitudinal ligament. *Spine* (1996) **21**, 1458-1466.
7. Muramoto T, Takemitsu Y, Iwahara T and Ozawa K: A clinical study on ossification of the posterior longitudinal ligament of the thoracic spine. *J Jpn Spine Surg* (1995) **6**, 49 (in Japanese).
8. Tsuzuki N, Abe R, Saiki I, Kondou Y, Wadano Y and Kikuchi S: Extensive cervicothoracic laminoplasty decompression for the thoracic myelopathy due to OPLL. *Rinsyo Seikeigeka* (1993) **28**, 303-311 (in Japanese).

Received July 7, 1998; accepted August 24, 1998.