

Acta Medica Okayama

Volume 47, Issue 2

1993

Article 10

APRIL 1993

Second malignant neoplasms after treatment for osteosarcoma: a report of three cases.

Toshifumi Ozaki*

Shinsuke Sugihara†

Hajime Inoue‡

*Okayama University,

†Okayama University,

‡Okayama Univeristy,

Second malignant neoplasms after treatment for osteosarcoma: a report of three cases.*

Toshifumi Ozaki, Shinsuke Sugihara, and Hajime Inoue

Abstract

We report second malignant neoplasms which developed between 7 and 19 years after treatment in 3 pediatric patients with osteosarcoma. Two patients had been treated with only surgery, and another patient had been treated with a combination of surgery with chemotherapy and radiation therapy for primary lesions. Pediatric patients with osteosarcoma, in particular, require careful long-term follow-up to monitor not only metastases but also development of second malignant neoplasms.

KEYWORDS: osteosarcoma, second malignancy

*PMID: 8506750 [PubMed - indexed for MEDLINE]

Copyright (C) OKAYAMA UNIVERSITY MEDICAL SCHOOL

Second Malignant Neoplasms after Treatment for Osteosarcoma: A Report of Three Cases.

Toshifumi Ozaki*, Shinsuke Sugihara, and Hajime Inoue

Department of Orthopaedic Surgery, Okayama University Medical School, Okayama 700, Japan

We report second malignant neoplasms which developed between 7 and 19 years after treatment in 3 pediatric patients with osteosarcoma. Two patients had been treated with only surgery, and another patient had been treated with a combination of surgery with chemotherapy and radiation therapy for primary lesions. Pediatric patients with osteosarcoma, in particular, require careful long-term follow-up to monitor not only metastases but also development of second malignant neoplasms.

Key words : osteosarcoma, second malignancy

Pediatric patients with osteosarcoma are at high risk for the development of second malignant neoplasms, even several years after the primary disease has been successfully treated. We report the development of second malignant neoplasms in 3 patients who survived for long time after treatment for osteosarcoma.

Case Presentation

Case 1. A 9-year-old girl complained of spontaneous pain in her left thigh in January, 1972. Plain radiography revealed periosteal reaction and bony destruction from the diaphysis to distal metaphysis of the left femur (Fig. 1-A). She was admitted to our hospital in February, 1972. Osteoblastic osteosarcoma was diagnosed based on histological examination of the biopsy specimen (Fig. 1-B). After disarticulation of the left hip, metastasis was detected in the lung on radiographs of the chest in June, 1972. She was admitted to the Pediatric Department and underwent intensive chemotherapy consisting of vincristine, adriamycin, and cyclophosphamide. In addition, radiation therapy (80 Grays) was delivered to the metastatic lesion. The patient had entered in complete remission by December, 1974. However, later, abdom-

inal pain and swelling developed in April, 1980. Papanicolaou-stained smears of ascites revealed class IV, indicating the high possibility of malignancy. Despite chemotherapy, she died in June, 1980. Autopsy revealed

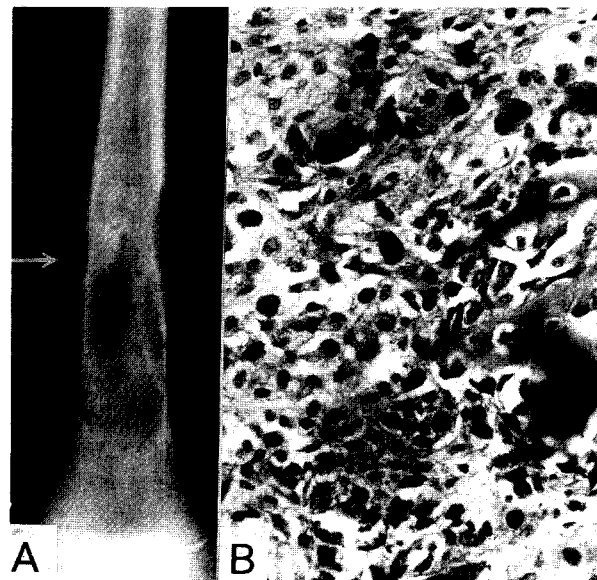


Fig. 1 Case 1. A: Radiograph reveals the periosteal reaction and bone destruction between the diaphysis and distal epiphysis of the left femur (arrow). B: Histology of the biopsy sample shows osteoblasts with atypical nuclei, mitoses, and osteoid formation (H. E., $\times 200$).

*To whom correspondence should be addressed.

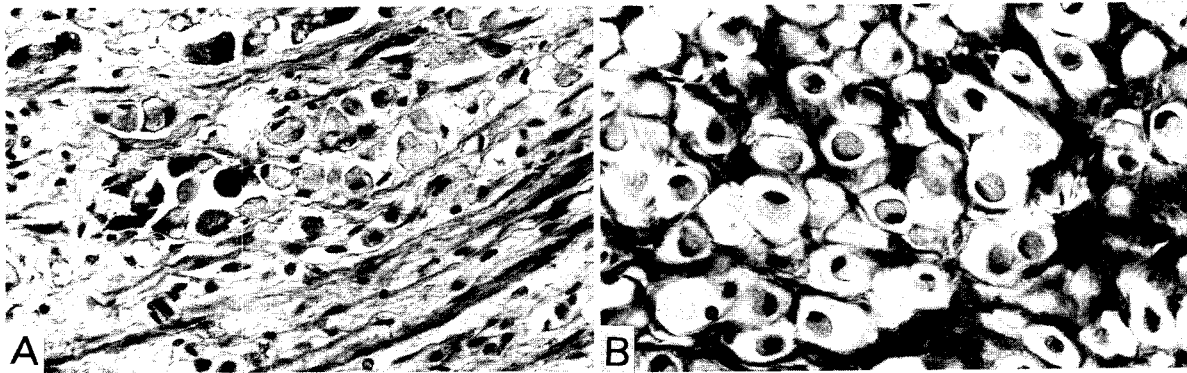


Fig. 2 Histological findings of second malignant neoplasms in Case 1. A: Signet-ring cells infiltrating in the gastric mucosa (H. E., $\times 200$). B: Signet-ring cells in the ovarian stroma (H. E., $\times 200$).

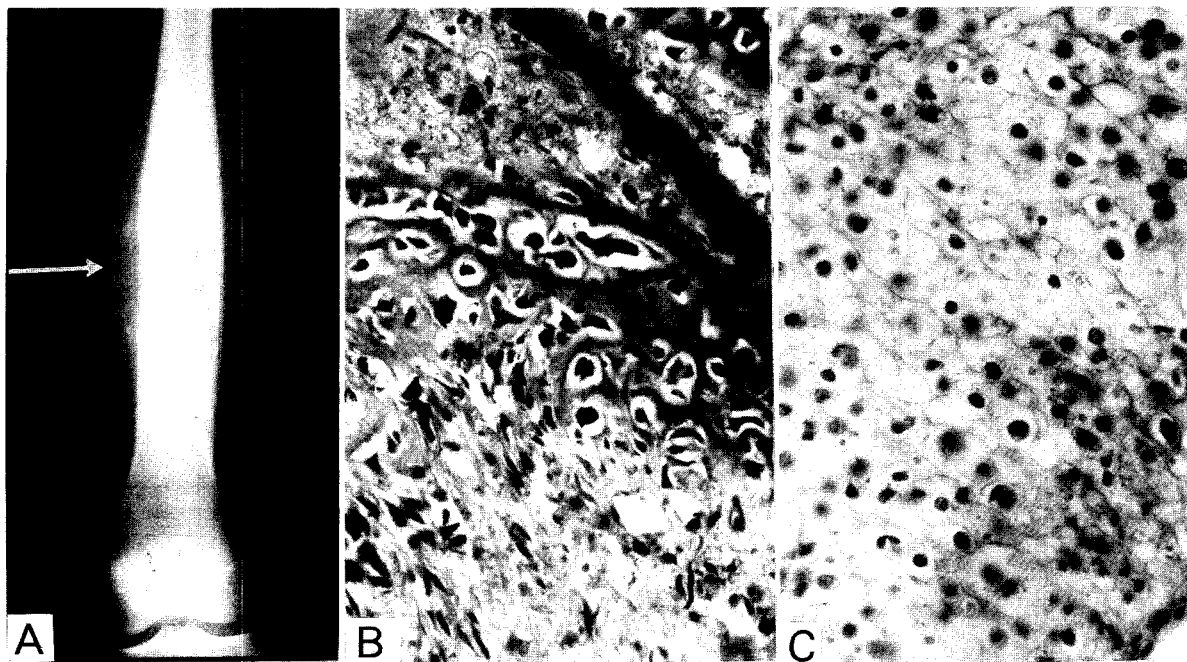


Fig. 3 Case 2. A: Plain radiograph at the first visit showing periosteal reaction of the diaphysis of the left femur (arrow). B: Typical osteoblasts with osteoid formation (H. E., $\times 200$). C: Chondroid substance (H. E., $\times 200$).

signet ring cells in the mucosa of the stomach (Fig. 2-A) and fibrous stroma of the ovary (Fig. 2-B), suggesting gastric cancer with metastasis to the ovary (Krukenberg's tumor).

Case 2. An 11-year-old girl had spontaneous pain in her left thigh, and was admitted to our hospital in May,

1971. Radiography revealed periosteal reaction of the diaphysis of the left femur (Fig. 3-A). Following histological diagnosis of osteosarcoma from the biopsy specimen (Fig. 3-B, C), disarticulation of the hip was performed in April, 1971. Although the patient had remained free from disease for 7 years and 1 month, a

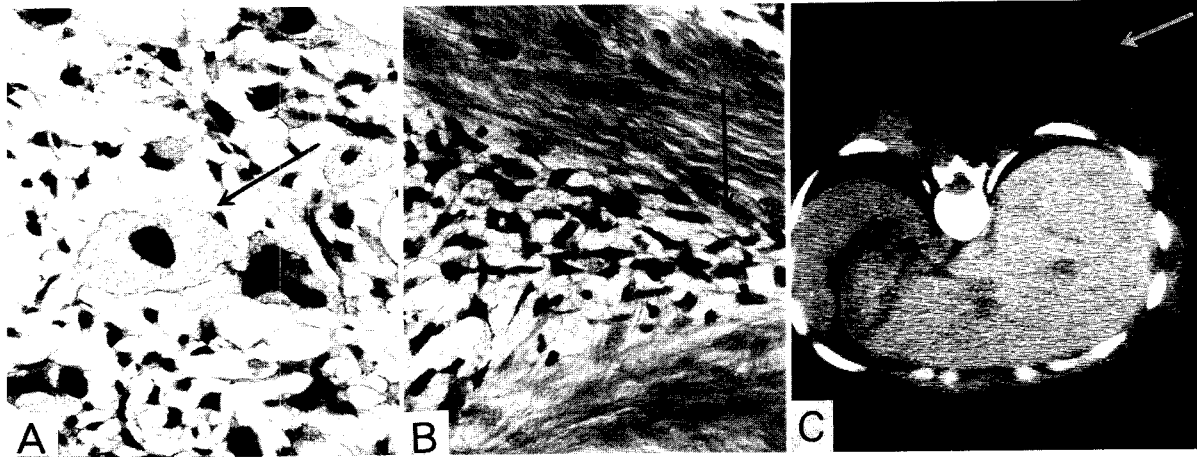


Fig. 4 Case 2. A: Pleomorphic liposarcoma consisting almost entirely of bizarre lipoblasts with hyperchromatic nuclei and numerous lipid droplets in the cytoplasm (arrow) (H. E., $\times 200$). B: Invasion of tumor cells into muscles (arrow) (H. E., $\times 200$). C: Computed tomography of the second malignant neoplasm (liposarcoma) on the back (arrow).

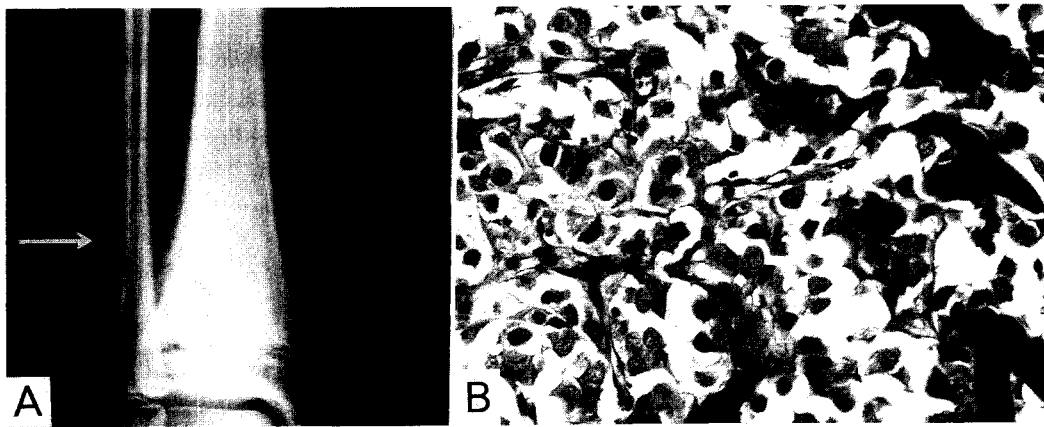


Fig. 5 Case 3. A: Plain radiograph at the first visit revealing periosteal reaction of the distal metaphysis of the right tibia (arrow). B: Characteristic osteoblastic pattern with osteoid formation (H. E., $\times 200$).

pea-sized tumor appeared on her back in June, 1978. Histologically, the tumor was a pleomorphic type of liposarcoma (Fig. 4-A, B). The tumor had recurred repeatedly and was extirpated 5 times between 1978 and 1983 (Fig. 4-C). Chest radiograph showed multiple metastatic nodules in June, 1983, and she died in November, 1983.

Case 3. A 10-year-old girl had complained of pain in her right ankle, and was admitted to our hospital in October, 1972. Radiography revealed periosteal reaction of the distal metaphysis of the right tibia (Fig. 5-A), and

a malignant bone tumor was strongly suspected. Amputation of the leg below the right knee was performed in the same month, 1972. Histologically, the diagnosis of osteoblastic osteosarcoma with considerable osteoid formation was confirmed (Fig. 5-B). She had remained free from disease for 19 years. However, a CT scan performed for abdominal pain, which started in November, 1991, revealed ascites and a large ovarian tumor (Fig. 6-A). She was admitted to the Gynecologic Department. Adenocarcinoma of the ovary was histologically diagnosed (Fig. 6-B). Despite chemotherapy, she died in

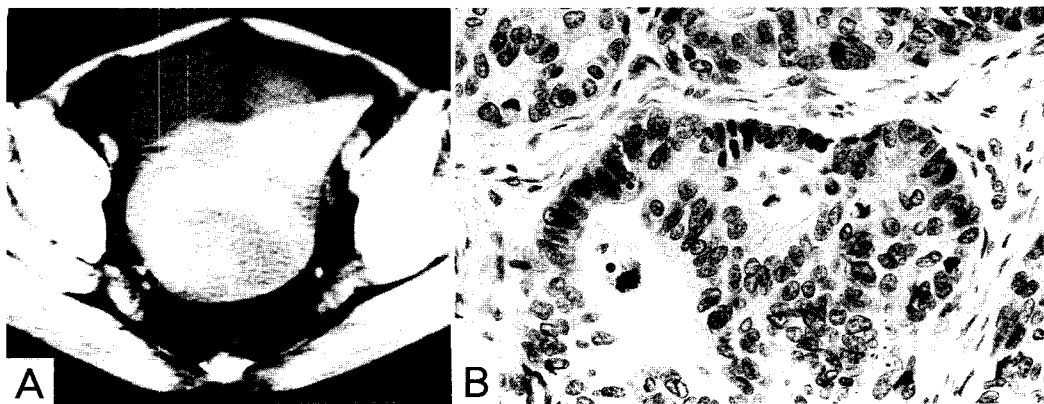


Fig. 6 Case 3. A: Computed tomography of the second malignant neoplasm (ovarian cancer). B: Histological examination of the resected ovary disclosed adenocarcinoma (H. E., $\times 200$).

January, 1992.

Discussion

Second malignant neoplasms often develop in children after treatment for cancer. Recently, as survival rate of patients with cancer has increased through intensive multiagent chemotherapy and radiation therapy, so have increased the reported numbers of second malignancies (1, 3). Li *et al.* reported that second malignant neoplasms developed in 12% of pediatric cancer cases (4), and Potish *et al.* reported the incidence within 30 years after the initial treatment to be 10% (5).

Reported second malignancies after treatment for osteosarcoma include each one case of pancreatic tumor (6), esophageal cancer (1), soft tissue tumor (4), and leukemia (7). Of our long survived 17 patients after treatment for osteosarcoma, 3 (18%) have developed second malignancy. This rate is higher than those reported in other types of primary malignancy (4, 5). Although malignant neoplasms are thought most frequently to develop 15 to 19 years after diagnosis of the first tumor (4), our three patients developed malignancy 7, 8 and 19 years, respectively, after the initial treatment.

Only surgery was performed in Cases 2 and 3, and a combination of surgery, chemotherapy including alkylating agents (cyclophosphamide), and radiation therapy for metastatic lung lesions, was performed in Case 1.

Although alkylating agents may induce second malignancy (8, 9), the incidence of malignant neoplasms among our patients shows no apparent relationship with types of therapy. Thus, genetic factors may be closely related to the oncogenesis of osteosarcoma and second malignancies. Currently, chemotherapy plays an important role in the treatment of malignant bone and soft tissue tumors. Survival rate of patients with osteosarcoma can be improved; in parallel, the incidence of second malignancies may also increase. Pediatric patients with osteosarcoma require careful long-term follow-up for the possibility of the second malignancy after treatment of the primary tumors.

References

1. Dewar JM, Courtney JT, Byrne MJ and Joske RA: Esophageal cancer in a young woman after treatment for osteosarcoma. *Med Pediatr Oncol* (1988) **16**, 287-289.
2. Kingstone JE, Hawkins MM, Draper GJ, Marsden HB and Wilson LMK: Patterns of multiple primary tumors in patients treated for cancer during childhood. *Br J Cancer* (1987) **56**, 331-338.
3. Mike V, Meadows AT and D'Angio GJ: Incidence of second malignant neoplasms in children: Results of an international study. *Lancet* (1982), **2**, 1326-1331.
4. Li FP: Second malignant tumors after cancer in childhood. *Cancer* (1977) **40**, 1899-1902.
5. Potish RA, Dehner LP, Haselow RE, Kim TH, Levitt, SH and Nesbit M: The incidence of second neoplasms following megavoltage radiation for pediatric tumors. *Cancer* (1985) **56**, 1534-1537.
6. Meadows AT, D'Angio GJ, Mike V, Banfi A, Harris C, Jenkin

- RDT and Schwartz A: Patterns of second malignant neoplasms in children. *Cancer* (1977) **40**, 1903-1911.
7. Orazi A, Sozzi G, Morandi F, Rottoli L and Cattoretti G: Acute monoblastic leukemia as a second malignancy following chemotherapy for osteogenic sarcoma: A case report. *Pediatr Hematol Oncol* (1988) **5**, 39-46.
8. Schmahl D, Hab M, Lorenz M and Wagner J: Occurrence of second tumors in man after anti-cancer drug treatment. *Cancer Treat Rev* (1982) **9**, 167-194.
9. Hawkins MM, Draper GJ and Kingston JE: Incidence of second primary tumors among childhood cancer survivors. *Br J Cancer* (1987) **56**, 339-347.

Received June 17, 1992; accepted July 29, 1992.