

Acta Medica Okayama

Volume 56, Issue 5

2002

Article 5

OCTOBER 2002

Hepatopancreatic arterial ring: bilateral symmetric typology in human celiaco-mesenteric arterial system.

Motohiro Kosaka*

Kanji Horiuchi[†]

Keiichiro Nishida[‡]

Takehito Taguchi**

Takuro Murakami^{††}

Aiji Ohtsuka^{‡‡}

*Okayama University,

[†]Okayama University,

[‡]Okayama University,

**Okayama University,

^{††}Okayama University,

^{‡‡}Okayama University,

Hepatopancreatic arterial ring: bilateral symmetric typology in human celiaco-mesenteric arterial system.*

Motohiro Kosaka, Kanji Horiuchi, Keiichiro Nishida, Takehito Taguchi, Takuro Murakami, and Aiji Ohtsuka

Abstract

The celiac and mesenteric arterial system including the left gastric, splenic, common hepatic, and superior mesenteric arteries shows various types of origins, courses, ramifications and anastomoses. In order to explain the various expressions of this system, we have proposed a typological model, in which celiacomesenteric arteries develop as paired or bilaterally symmetrical primordial vessels originated from the anterior aspect of the aorta, and these vessels anastomose each other with longitudinal and horizontal pathways. Here, we report 3 unusual cases characterized by arterial rings, formed by the left gastric, left accessory hepatic, proper hepatic, anterior pancreaticoduodenal, and dorsal pancreatic arteries. The dorsal pancreatic and anterior pancreaticoduodenal arteries are located to the right and left of the embryonic pancreas developing in the dorsal mesentery, respectively. Such hepatopancreatic arterial rings simultaneously containing right and left elements can only be explained using our typological model, in which the concept of paired arteries or bilateral symmetry is introduced.

KEYWORDS: arterial variation, celiac trunk, superior mesenteric artery, typology, bilateral symmetry

*PMID: 12530508 [PubMed - indexed for MEDLINE]

Copyright (C) OKAYAMA UNIVERSITY MEDICAL SCHOOL

Original Article

Hepatopancreatic Arterial Ring: Bilateral Symmetric Typology in Human Celiac-Mesenteric Arterial System

Motohiro Kosaka^a, Kanji Horiuchi^a, Keiichiro Nishida^b, Takehito Taguchi^c,
Takuro Murakami^a, and Aiji Ohtsuka^{a*}

^aDepartment of Human Morphology, ^bDepartment of Orthopaedic Surgery, Okayama University Graduate School of Medicine and Dentistry, and ^cDepartment of Radiological Technology, Faculty of Health Sciences, Okayama University Medical School, Okayama 700–8558, Japan

The celiac and mesenteric arterial system including the left gastric, splenic, common hepatic, and superior mesenteric arteries shows various types of origins, courses, ramifications and anastomoses. In order to explain the various expressions of this system, we have proposed a typological model, in which celiacomesenteric arteries develop as paired or bilaterally symmetrical primordial vessels originated from the anterior aspect of the aorta, and these vessels anastomose each other with longitudinal and horizontal pathways. Here, we report 3 unusual cases characterized by arterial rings, formed by the left gastric, left accessory hepatic, proper hepatic, anterior pancreaticoduodenal, and dorsal pancreatic arteries. The dorsal pancreatic and anterior pancreaticoduodenal arteries are located to the right and left of the embryonic pancreas developing in the dorsal mesentery, respectively. Such hepatopancreatic arterial rings simultaneously containing right and left elements can only be explained using our typological model, in which the concept of paired arteries or bilateral symmetry is introduced.

Key words: arterial variation, celiac trunk, superior mesenteric artery, typology, bilateral symmetry

Three unpaired arteries — the celiac trunk and the superior and inferior mesenteric arteries — usually originate from the anterior aspect of the abdominal aorta, and supply the abdominal digestive organs and spleen. Among these, the celiac trunk, a wide ventral branch just below the aortic hiatus, passes almost horizontally forward of and slightly above the pancreas and splenic vein, then dividing into the following: the left gastric, common hepatic, and splenic arteries. These three and the superior mesenteric arteries vary in terms of pattern of origins, courses, ramifications, and anas-

tomoses [1–14]. The celiac trunk or its branches may also give off one or both (left and right) the inferior phrenic arteries [15]. These variations have been classified and explained using classical typological models [16, 17]. The classical models are characterized by 4 longitudinally anastomosed vessels (left gastric, splenic, common hepatic, and superior mesenteric), which independently originate from the abdominal aorta. Some common variations, such as hepatomesenteric trunk or independent origin of left gastric artery, are well accounted for using this classic model, although it does not explain the formation of some rare variations such as hepatogastric or splenomesenteric trunk formation. Previously, we presented typological diagrams of the phrenico-celiaco-mesenteric arterial system [8, 9, 15]. These

Received March 7, 2002; accepted May 23, 2002.

*Corresponding author. Phone: +81-86-235-7089; Fax: +81-86-235-7095
E-mail: aiji@md.okayama-u.ac.jp (A. Ohtsuka)

diagrams were useful for introducing the concept of left-right bilaterality to explain several unpaired or unilateral variations in this arterial system.

In the present study, we present rare anomalous cases characterized by arterial ring formation of the left gastric-left accessory hepatic-proper hepatic-anterior pancreaticoduodenal-dorsal pancreatic arteries. For explanation of such arterial ring formation, the bilaterality concept is required; some segments of the ring belong to the right system, others to the left.

Materials and Methods

In 1996-2000, we encountered significant hepatopancreatic arterial rings in 3 Japanese adult cadavers. Age, sex, clinical diagnosis at death, and abdominal surgical history of these cases are summarized in Table 1. Cadavers were fixed conventionally by arterial perfusion with 10% formalin through the right or left radial artery, and subsequently dehydrated with 50-60% ethanol at 40 °C. Until dissection, they were stored, for 6 months or longer, in a stainless-steel body storage system (Katoman, Tokyo, Japan). Dissection was performed in

a human gross anatomy course for medical students at the Okayama University Medical School.

Results

Case 1. (Fig. 1). The left gastric and splenic arteries formed a common trunk with the left inferior phrenic artery and arose from the anterior aspect of the abdominal aorta beneath the aortic hiatus. This phrenico-gastro-splenic trunk immediately gave off the left inferior phrenic artery, and divided into the left gastric and splenic arteries behind the omental bursa. The left gastric artery ascended along the left gastropancreatic fold and reached the upper end of the lesser curvature of the stomach. The left accessory hepatic artery issued from the left gastric artery in the left gastropancreatic fold, then ran along the fissure for the ligamentum venosum in the lesser omentum, giving a branch to the esophagus, and reached the hepatic portal region. The splenic artery gave off the anterior right accessory hepatic artery [11] at the upper margin of the pancreatic body, ran left along the pancreas, and reached the hilum of the spleen through the phrenicolienal ligament. The anterior right accessory hepatic artery descended on the posterior aspect of the pancreas, turned right at its lower margin to appear in front of the portal vein, and ascended on the pancreatic anterior surface, where it branched off the anterior superior pancreaticoduodenal, right gastroepiploic, and posterior superior pancreaticoduodenal arteries. The anterior right accessory hepatic artery, giving off the right gastric artery to the lesser curvature of the stomach, ascended further in the hepatoduodenal ligament along the

Table 1 General description of the cases

Case	Sex	Age	Diagnosis at death	Abdominal surgical history
1	Male	83 y	Lung cancer	No
2	Female	83 y	Pneumonia	No
3	Male	73 y	Cerebral infarction	No

y, year old.

Table 2 Abbreviations in Figures 1-3, 5, and 6

a: abdominal aorta	m2: left and right upper ventricular arteries	u: umbilical artery
c: intercostal (or lumbar) artery	m3: left and right middle ventricular arteries	v: portal vein
d: dorsal pancreatic artery	m4: left and right lower ventricular arteries	w: gastroduodenal artery
e: superior anterior pancreaticoduodenal artery	m5: left and right upper intestinal (superior mesenteric) arteries	x: accessory gastric artery
f: inferior anterior pancreaticoduodenal artery	m6: left and right lower intestinal (inferior mesenteric) arteries	y: right gastric artery
g: left gastric artery	n: renal artery	B: common bile duct
h: common hepatic artery	o: left accessory hepatic artery	D: duodenum
i: inferior phrenic artery	p: proper hepatic artery	G: gall bladder
ii: internal iliac artery	r: right gastroepiploic artery	H: liver
k1: anterior right accessory hepatic artery	s: splenic artery	I: intestine
k2: posterior right accessory hepatic artery	t: testicular (ovarian) artery	K: kidney
k3: left accessory hepatic artery	ti: internal thoracic artery	P: pancreas
m: superior mesenteric artery		S: stomach
m1: left and right subphrenic arteries		Sp: spleen

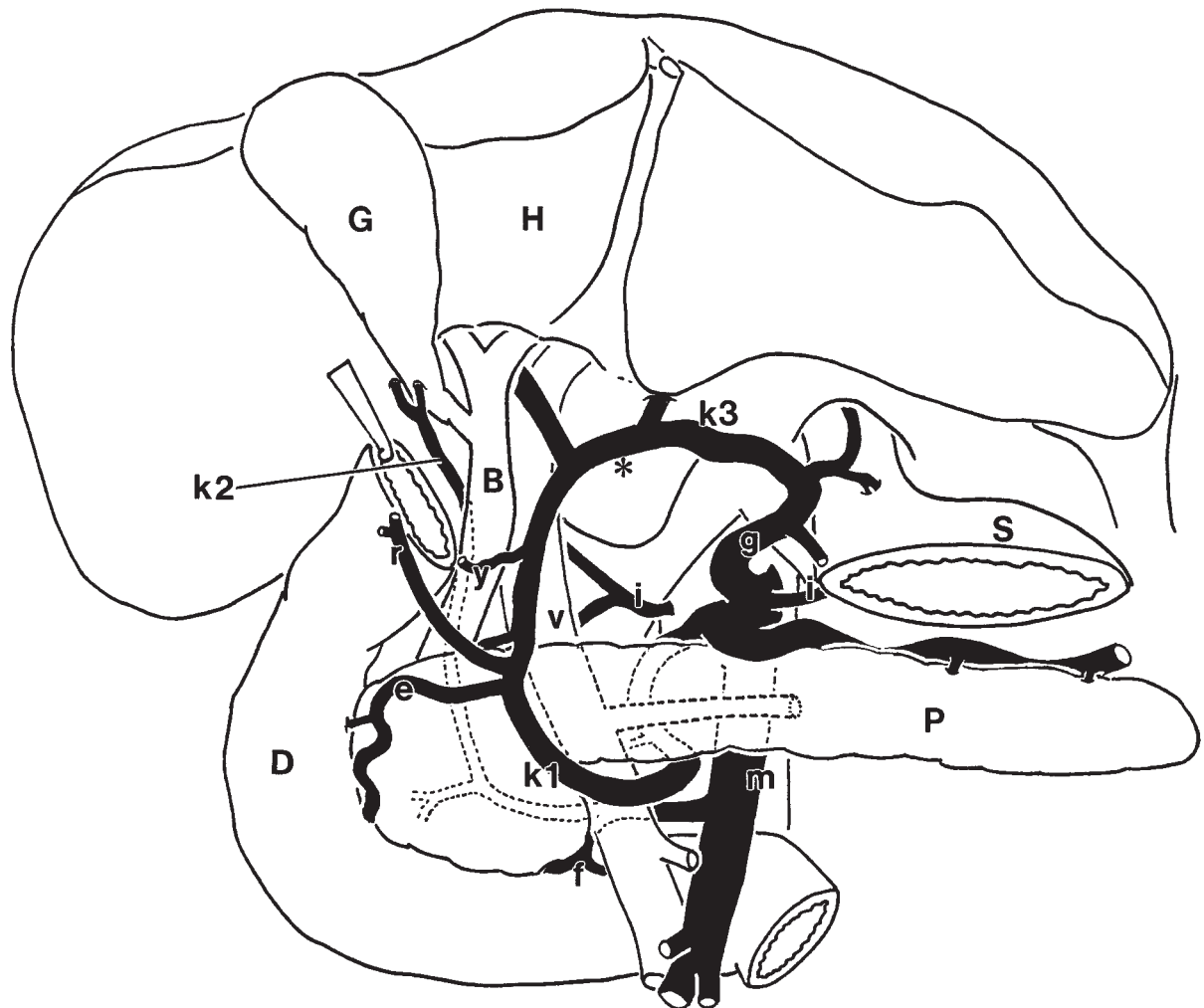


Fig. 1 Line drawing representation of case 1. Three aberrant accessory hepatic arteries (k1, k2, and k3) co-exist, and the common hepatic artery is lost. Note a complete arterial ring made of anastomosed left and right accessory hepatic arteries (asterisk). Abbreviations: see Table 2.

anterior side of the portal vein, and reached the hepatic portal region, where the anterior right accessory hepatic and left accessory hepatic arteries anastomosed to form an arterial arch. Thus, these accessory hepatic arteries formed an arterial ring around the pancreas and lesser omentum. The right and left hepatic branches arose from this hepatic arterial arch. Additionally, the superior mesenteric artery issued the posterior right accessory hepatic artery, which ran posteriorly to the portal vein on the back side of the pancreas, where it gave off branches to the pancreas and the duodenum, then ascended behind the common bile duct and portal vein to reach the gall bladder and the hepatic right lobe and to supply them.

Case 2. (Fig. 2). The left gastric and splenic arteries formed a common trunk (gastro-splenic trunk), which arose from the anterior aspect of the abdominal aorta. The left gastric artery ran through the left gastropancreatic fold to the lesser curvature of the stomach. The splenic artery, after issuing the dorsal pancreatic artery, ran along the superior border of the pancreas, and reached the spleen. The dorsal pancreatic artery descended from the posterior aspect of the pancreas toward its inferior margin, where it became the inferior pancreatic artery. The superior mesenteric artery originated from the aorta just inferior to the gastro-splenic trunk, and issued the posterior right accessory hepatic artery. This

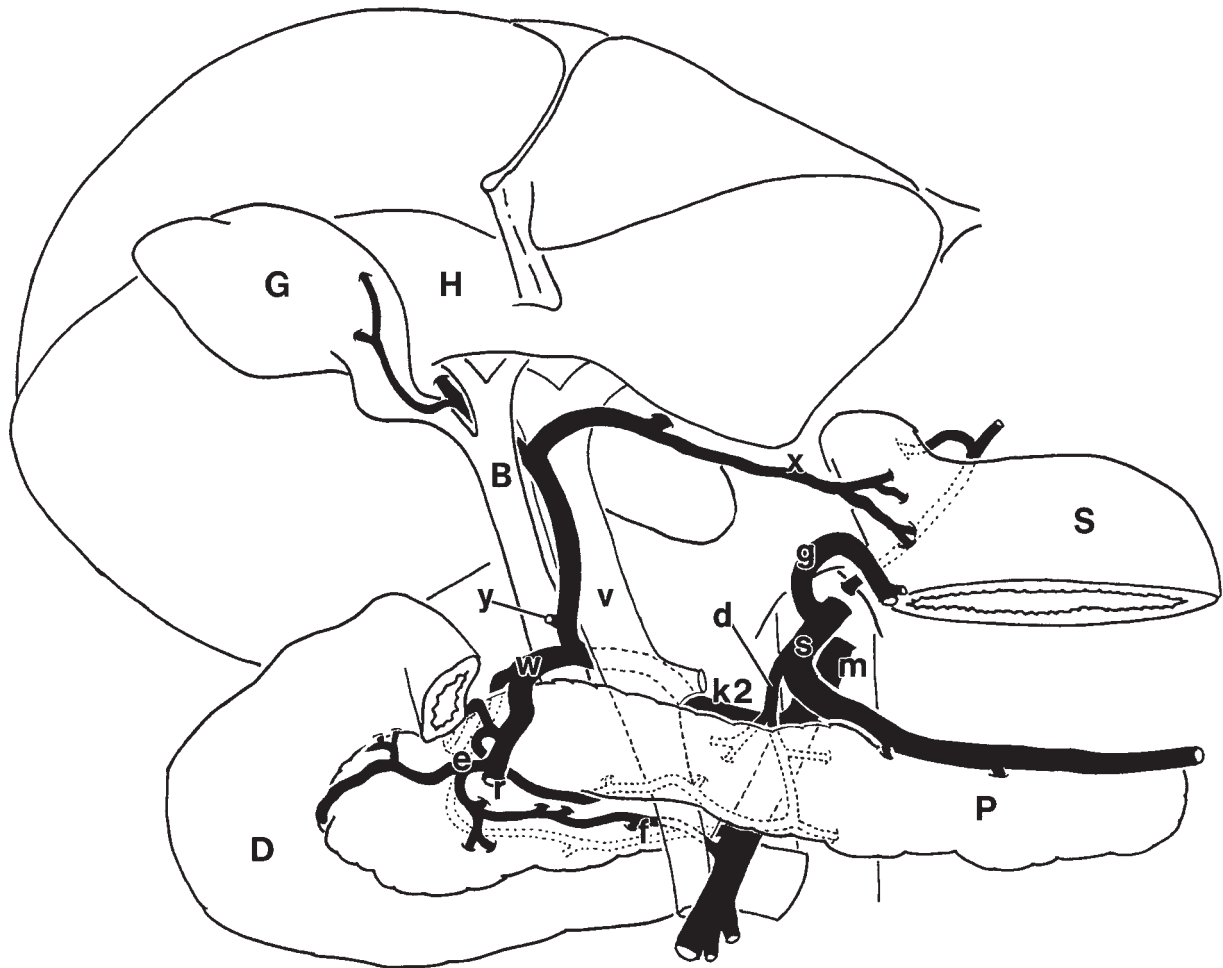


Fig. 2 Line drawing representation of case 2. The lack of a usual common hepatic artery is compensated for by an anomalous posterior right accessory hepatic artery (k2), which runs behind the portal vein. Note an arterial ring made of the accessory hepatic (k2), gastroduodenal (w), pancreaticoduodenal (e), and superior mesenteric (m) arteries. Other abbreviations: see Table 2.

accessory hepatic artery passed behind the portal vein and ran between the common bile duct and the portal vein to appear in front of the bile duct, where this artery bifurcated into the gastroduodenal and proper hepatic arteries. The proper hepatic artery, after branching off the right gastric artery, ascended along the anterior aspect of the portal vein to reach the porta hepatis, where it divided into right and left branches. The right branch passed through behind the hepatic duct, issued a branch to the gall bladder, and entered the right lobe of the liver. The left branch, running along the fissure for the ligamentum venosum, gave a thick branch to the hepatic left lobe, and finally became the accessory gastric artery, which coursed along the upper margin of the lesser omentum to supply

the cardia and fundus of the stomach. The gastroduodenal artery gave off the superior posterior pancreaticoduodenal artery, which ran on the posterior surface of the pancreas and anastomosed with the inferior posterior pancreaticoduodenal artery. Subsequently, the gastroduodenal artery gave the pancreatic head a branch, which in turn anastomosed with the inferior pancreatic artery (see above). Then the gastroduodenal artery divided into the right gastroepiploic artery and the superior anterior pancreaticoduodenal artery. The latter made an arterial arcade with the inferior anterior pancreaticoduodenal artery, which was derived from the superior mesenteric artery. Thus, arterial rings around the pancreas were

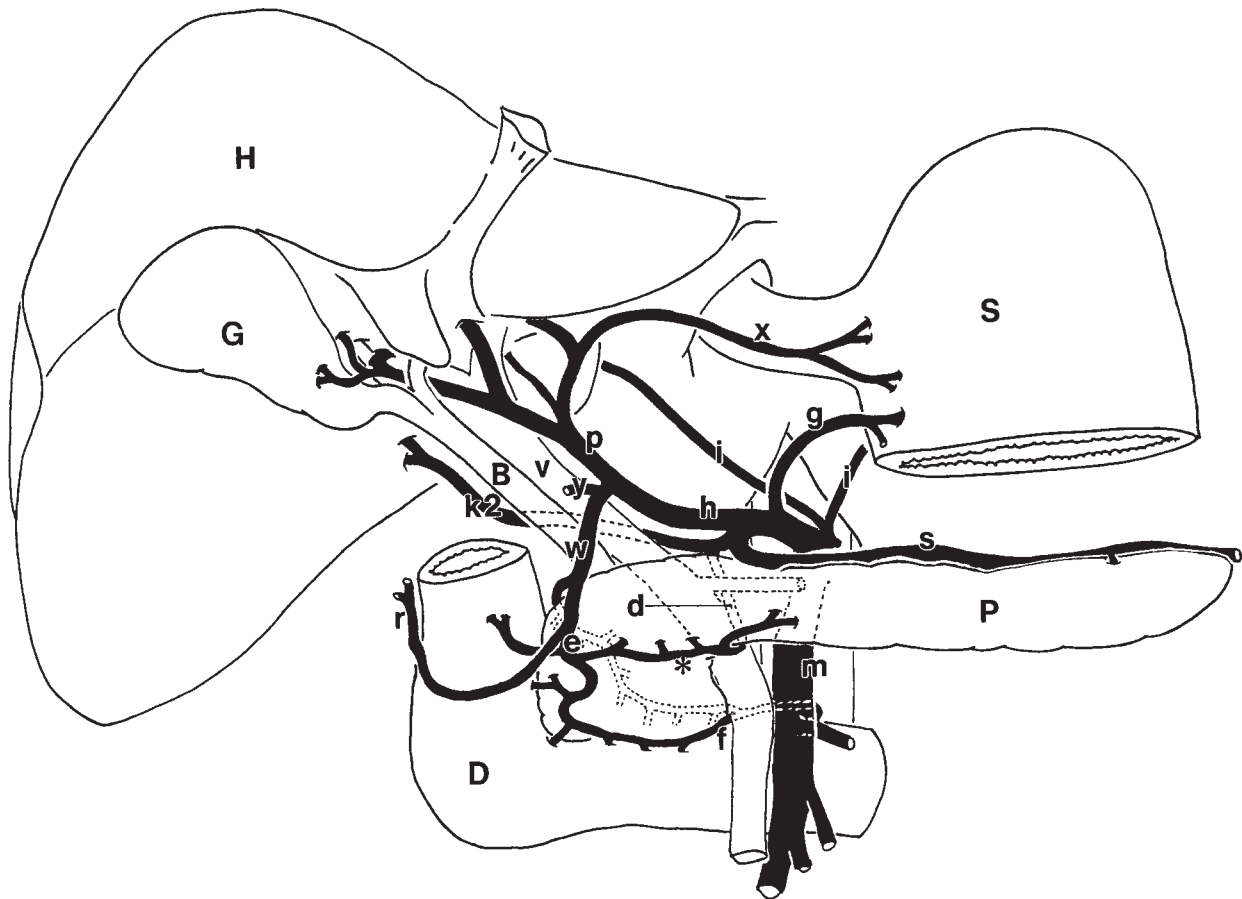


Fig. 3 Line drawing representation of case 3. An anomalous artery, the posterior right accessory hepatic (k2), is originated, making a common trunk with the dorsal pancreatic artery, from the splenic artery. Note that an arterial ring around the pancreas is formed by a thick connection of the pancreaticoduodenal and dorsal pancreatic arteries (asterisk). Other abbreviations: see Table 2.

comprised of the superior mesenteric, posterior right accessory hepatic, gastroduodenal, and superior and inferior pancreaticoduodenal arteries.

Case 3. (Fig. 3). The celiac trunk arose as usual (*i.e.*, as the gastro-spleno-hepatic trunk) from the anterior aspect of the abdominal aorta. The left gastric artery reached the cardiac region of the lesser curvature; the common hepatic artery emitted the proper hepatic artery, which ran in front of the portal vein to the porta hepatis, where it provided the accessory gastric artery and gave the right gastric artery to the pyloric region of the lesser curvature, then became the gastroduodenal artery. The gastroduodenal artery branched off the posterior superior pancreaticoduodenal artery at the upper margin of the pancreatic head, and bifurcated into the right gastroepiploic and anterior superior pancreaticoduodenal arteries at

the anterior aspect of the pancreas. The splenic artery gave off a common trunk of the posterior right accessory hepatic and dorsal pancreatic arteries. This accessory hepatic artery passed behind the portal vein and the common bile duct, and ran to the right lobe of the liver. The dorsal pancreatic artery descended on the posterior aspect of the pancreatic body, and appeared on the anterior aspect of the pancreatic head, where it anastomosed with a branch of the anterior superior pancreaticoduodenal artery. Here, a chain of the common hepatic, gastroduodenal, anterior superior pancreaticoduodenal, dorsal pancreatic, posterior right accessory hepatic, and splenic arteries formed an arterial ring around the pancreas. The inferior pancreaticoduodenal artery arose from the superior mesenteric artery, and divided into the 2 branches, anterior and posterior, which

in turn anastomosed with the anterior and posterior superior pancreaticoduodenal arteries, respectively.

Discussion

The present study reported 3 cases of complete and incomplete arterial rings in the celiaco-mesenteric arterial system around the pancreas and liver. The arterial ring in case 1 consisted of a chain comprised of the splenic, anterior right accessory hepatic, accessory gastric, and left gastric arteries. In case 2, the ring was formed by connection of the superior mesenteric, posterior right hepatic, gastroduodenal, anterior superior pancreaticoduodenal, and anterior inferior pancreaticoduodenal arteries. In case 3, the ring was comprised of the common hepatic, gastroduodenal, anterior superior pancreaticoduodenal, dorsal pancreatic and posterior right accessory hepatic arteries. Our previous typological diagrams [8, 9] (Fig. 4) were modified or revised in order to explain the formation of these arterial rings seen in the present cases (Fig. 5A). Explanations of the present cases are given using this modified typological model (Fig. 5B-D).

The present cases show anomalous hepatic arteries, particularly the anterior and posterior right accessory hepatic arteries. The anterior right accessory hepatic artery in case 1 is considered to have compensated with thickening of the anterior superior-inferior pancreaticoduodenal arteries for the lack of a typical common hepatic artery [11]. The posterior right hepatic artery in case 2 is considered to be an unusually developed vessel from the posterior superior-inferior pancreaticoduodenal arteries and nutrient arteries of the bile duct. The posterior right accessory hepatic artery in case 2 seems to have derived from pancreatic branches of the superior mesenteric artery [12]. In case 3, an unusually developed branch of the dorsal pancreatic artery might have become this anomalous hepatic artery [6].

Generally, it is well known that the celiaco-mesenteric system shows numerous variations in its branching and originating pattern. Adachi [1] exhaustively investigated 252 cases and classified the variational patterns into 5 types based on the combination of origins and trunk formation of the left gastric, splenic, common hepatic, and superior mesenteric arteries. According to his system, the present case 1, case 2, and case 3 are classified as Adachi's Type VI, Type VI, and Type I, respectively. Morita [16] encountered a case that could not be

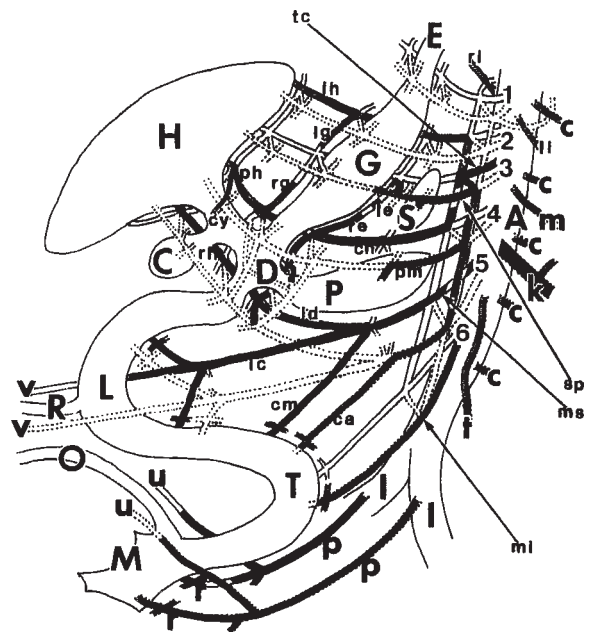


Fig. 4 A typological diagram previously demonstrated by Murakami *et al.* (1998). This diagram is reproduced for comparison with our diagram (Fig. 5). The darkly shaded vascular routes indicate an ordinary pattern of the celiacomesenteric system. Hepatopancreatic arterial rings in the present cases are not easily explainable using the previous model. The arteries labeled 1, 2, 3, 4, 5, and 6 correspond to m1, m2, m3, m4, m5, and m6 in Fig. 5, respectively. (Organs) C, gall bladder; D, duodenum; E, esophagus; G, stomach; H, liver; L, intestine; M, cloaca; O, allantois; P, pancreas; R, vitelline duct; T, hindgut; V, portal vein. (Celiaco-mesenteric arteries) 1, left and right subphrenic arteries; 2, left and right upper ventricular arteries; 3, left and right middle ventricular arteries; 4, left and right lower ventricular arteries; 5, left and right upper intestinal arteries; 6, left and right lower intestinal arteries; ca, accessory middle colic artery; ch, common hepatic artery, cm, middle colic artery; cy, cystic artery; ic, ileocolic artery; id, inferior pancreaticoduodenal artery; le, left gastroepiploic artery; lg, left gastric artery; lh, left accessory hepatic artery; li, left inferior phrenic artery; mi, inferior mesenteric artery; ms, superior mesenteric artery; ph, proper hepatic artery; pm, pancreatic branch (arteria pancreatica magna); re, right gastroepiploic artery; rg, right gastric artery; rh, right accessory hepatic artery; ri, right inferior phrenic artery; sd, superior pancreaticoduodenal artery; sp, splenic artery; tc, celiac trunk. (Other arteries) A, abdominal aorta; c, intercostal or lumbar arteries; k, left renal artery; l, common iliac arteries; m, left middle adrenal artery; p, inner iliac arteries; t, left testicular or ovarian artery; u, umbilical or supravesical arteries; v, vitelline arteries. Reproduced with permission from [9].

classified as one of Adachi's types, and considered theoretically a typological model of the celiaco-mesenteric arterial system. His model explained variational patterns

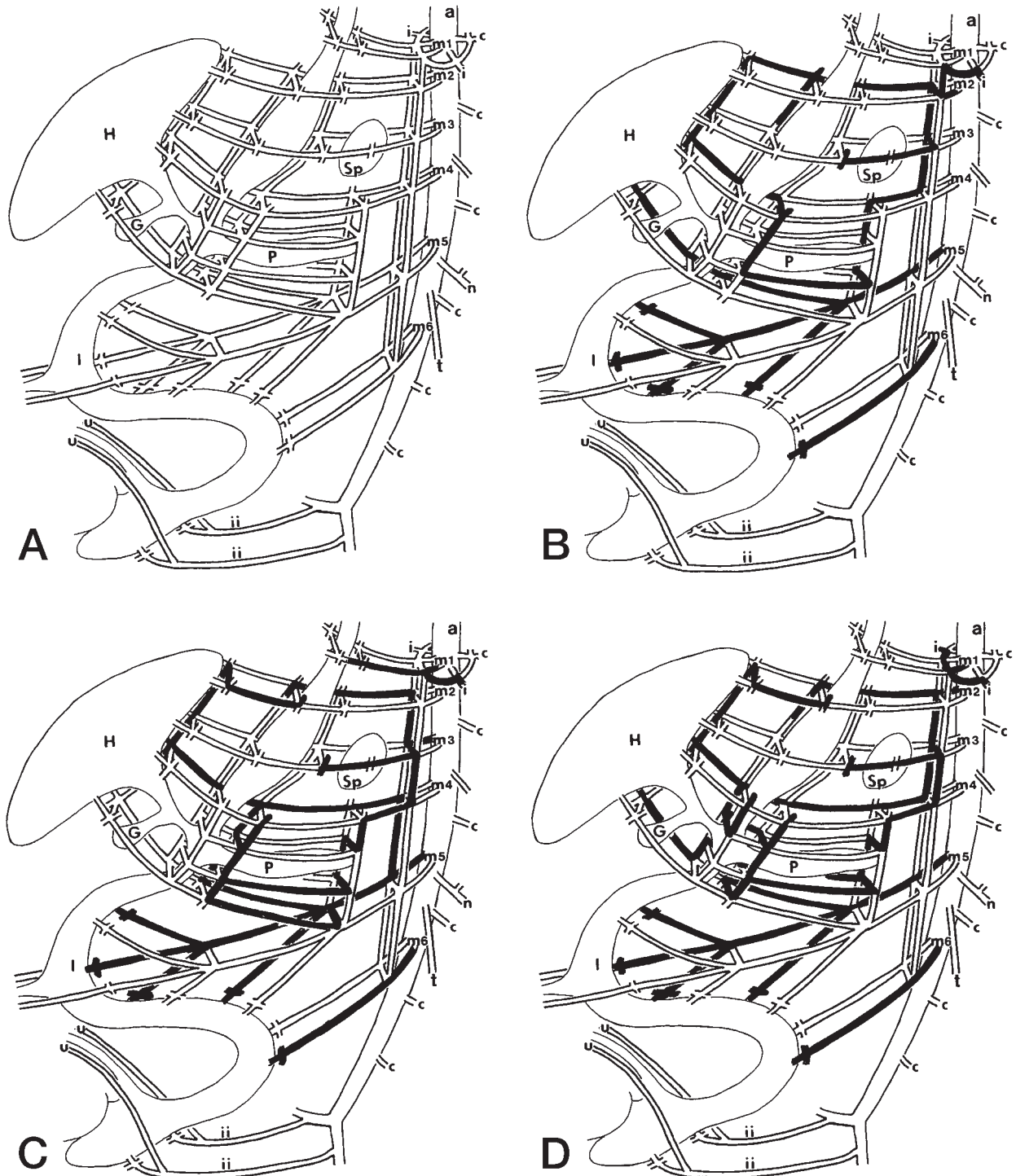


Fig. 5 A typical pattern of the celiaco-mesenteric arteries at an early stage of the fetal period (viewed from the left side), modified after Murakami *et al.* (1998) (A), and typical demonstrations of case 1 (B), case 2 (C), and case 3 (D) using this diagram. The gastrointestinal loop (I), liver (H), gall bladder (G), pancreas (P), and spleen (Sp) are supplied by the 6 sets of paired vessels: left and right subphrenic arteries (m1), left and right upper ventricular arteries (m2), left and right middle ventricular arteries (m3), left and right lower ventricular arteries (m4), left and right upper intestinal (superior mesenteric) arteries (m5), and left and right lower intestinal (inferior mesenteric) arteries (m6). These paired vessels are connected by horizontal and longitudinal anastomoses. Other abbreviations: see Table 2.

by four unpaired vessels (left gastric, splenic, hepatic, and superior mesenteric arteries) that originated from the anterior aspect of the abdominal aorta and were connected by longitudinal anastomosing vessels. This longitudinal anastomosis is based on Tandler's observation of the human embryo [17]. Morita's model well explained common variations such as independent origin of the left gastric artery or trunk formation of gastro-splenic and hepato-mesenteric trunk. Furthermore, his model predicted the independent origins of the 4 vessels, which rare anomaly has been reported by several groups, including ours [9]. However, his model cannot explain some very rare anomalies, such as gastro-hepatic and spleno-mesenteric trunk formation that avoids crossover of the vessels [5]. In contrast, our bilateral typological model, can demonstrate such rare trunk formation.

Our typological model of the mesenteric arterial system is characterized by the 5 pairs of intestinal arteries originating from the aorta and their longitudinal and horizontal anastomoses (Figs. 5A, 6). Felix [18] investigated the development of the abdominal arteries in the human embryo. In the early stage, paired dorsal aortae develop and emit branches laterally to the primitive intestine or yolk sac. These branches bilaterally create the intestinal arterial net. The mesenteric arteries, or celiacomesenteric arterial system, which is derived from the omphalomesenteric arteries, originally develop from the bilaterally symmetrical intestinal arterial net.

The arterial ring formation in the present cases strongly suggests a paired bilateral arterial system in the mesentery. The pancreas was developed in the posterior mesentery, and the stomach was rotated, with its right aspect facing behind. The arterial segment that runs behind the pancreas derives from the right system; the segment that runs in front of the pancreas derives from the left system; and the segment of the left gastric artery to the hepatic portal belongs to the right system. Thus, these cases of arterial rings around the pancreas are explained as the continuation of the right and left arterial system. It is noteworthy that longitudinal anastomosis commonly appeared in other sites of the body in these cases. For example, the longitudinal anastomosis at the anterior thoracic and abdominal wall (anterior parietal) remains as the internal thoracic and superior and inferior epigastric arterial axis (Fig. 6). In the arterial system of the scalenus region, a typological diagram introducing precostal longitudinal anastomoses between intersegmental arteries can explain various patterns of origination

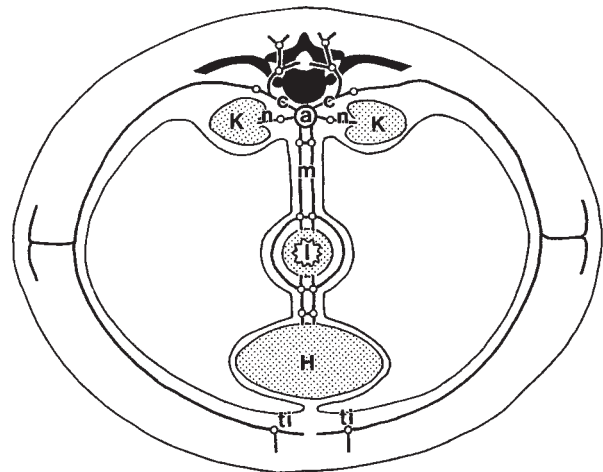


Fig. 6 Schematic diagram representing bilateral symmetry of the mesenteric arterial system and other parietal and visceral arteries. Longitudinal anastomoses are indicated by open circles (○). Abbreviations: see Table 2.

and branching [19]. In the celiacomesenteric arterial system, variational patterns of trunk formation and branching are well explained using longitudinal anastomotic vessels between segmental mesenteric arteries. Thus, longitudinal anastomotic vessels play an important role in the morphogenesis of the parietal and visceral vascular systems.

Acknowledgements. We would like to thank Mr. Hisao Mizoguchi, Mr. Masahiro Narasaki and Mr. Hiroyuki Osugi for their technical help. And, we specially appreciate honest works of Mr. Hiromichi Kusano, who was killed in an accident.

References

1. Adachi B: Aorta abdominalis; in *Das Arteriensystem der Japaner II*, Maruzen Co., Kyoto (1928) pp 11-129.
2. Feigl W, Firbas W, Sinzinger H and Wicke L: Variabilität des Truncus coeliacus und seiner Anastomosen mit der Arteria mesenterica superior. *Acta Anat* (1975) **92**, 272-284.
3. Okada S, Ohta Y, Shimizu T, Nakamura M and Yaso K: A rare anomalous case of absence of the celiac trunk — the left gastric, the splenic and the common hepatic arteries arose from the abdominal aorta independently. *Okajimas Folia Anat Jpn* (1983) **60**, 65-71.
4. Yamaki K, Tanaka N, Matsushima T, Miyazaki K and Yoshizuka M: A rare case of absence of the celiac trunk: The left gastric, the splenic, the common hepatic and the superior mesenteric arteries arising independently from the abdominal aorta. *Anat Anz* (1995) **177**, 97-100.
5. Kitamura S, Nishiguchi T, Sakai A and Kumamoto K: Rare case of the inferior mesenteric artery arising from the superior mesenteric artery. *Anat Rec* (1987) **217**, 99-102.
6. Matsumura H: The significance of the morphology of the dorsal

- pancreatic artery in determining the presence of the accessory right hepatic artery passing behind the portal vein. *Kaibogaku Zasshi (Acta Anat Nippon)* (1998) **73**, 517-527.
7. Michels NA: Blood supply and anatomy of the upper abdominal organs, with descriptive atlas. Lippincot, Philadelphia (1955) pp 3-459.
 8. Murakami T, Ohtsuka A and Piao DX: Typology of the human coeliac, left gastric, splenic, hepatic, superior mesenteric, inferior mesenteric and inferior phrenic arteries. *Okayama Igakkai Zasshi (JOMA)* (1995) **107**, 219-226 (in Japanese with English abstract).
 9. Murakami T, Mabuchi M, Giuvarasteanu I, Kikuta A and Ohtsuka A: Coexistence of rare arteries in the human celiaco-mesenteric system. *Acta Med Okayama* (1998) **52**, 239-244.
 10. Nelson TM, Pollak R, Jonasson O and Abcarian H: Anatomic variants of the celiac, superior mesenteric and inferior mesenteric arteries and their clinical relevance. *Clin Anat* (1988) **1**, 75-91.
 11. Ohtsuka A, Kikuta A and Murakami T: Common hepatic artery ascending on the anterior surface of the pancreas and left renal vein running beneath the diaphragm. *Okajimas Folia Anat Jpn* (1984) **60**, 427-434.
 12. Outi H, Kato N, Tajiri S and Murakami T: Variations of celiac trunk as observed in 1958-1964, with special reference to the left gastric and accessory hepatic arteries [Abstract]. *Kaibogaku Zasshi (Acta Anat Nippon)* (1965) **40**, 35 (in Japanese).
 13. McVay CB: Abdominal cavity and contents; in *Surgical Anatomy*, Anson and McVay eds, 6th Ed, Vol. I Part IV, The Abdomen, Philadelphia, (1984) pp 585-777.
 14. Zwerina H and Poisel S: Über eine Anastomose zwischen dem Truncus coeliacus, der Arteria mesenterica superior und der Arteria mesenterica inferior mit anderen Varietäten unpaarigen und paarigen Äste der Baucharterie beim Individuum. *Anat Anz* (1966) **119**, 427-435.
 15. Piao DX, Ohtsuka A and Murakami T: Typology of abdominal arteries, with special reference to inferior phrenic arteries and their esophageal branches. *Acta Med Okayama* (1998) **52**, 189-196.
 16. Morita M: Reports and conception of three anomalous cases on the area of the celiac and superior mesenteric arteries. *Igaku Kenkyu* (1935) **9**, 1993-2006 (in Japanese).
 17. Tandler J: Über der Varietäten der Arteria coeliaca und deren Entwicklung. *Anat Hefte* (1904) **25**, 473-500.
 18. Felix W: Zur Entwicklungsgeschichte der Rumpfartern des menschlichen Embryo. *Gegenbaurs Morphol Jahrb* (1910) **41**, 577-614.
 19. Su W-D, Ohtsuka A, Taguchi T and Murakami T: Typology of the arteries in the human scalenus region, with special reference to the accessory ascending cervical artery. *Acta Med Okayama* (2000) **54**, 243-252.