

Acta Medica Okayama

Volume 54, Issue 2

2000

Article 6

APRIL 2000

Creation and use of a composite polyurethane-expanded polytetrafluoroethylene graft for hemodialysis access.

Atsunori Nakao*

Masashi Miyazaki[†]

Yoshinari Oka[‡]

Hiroaki Matsuda**

Masahiro Oishi^{††}

Yoshiaki Kokumai^{‡‡}

Keiichi Kunitomo[§]

Hiroshi Isozaki[¶]

Noriaki Tanaka^{||}

*Okayama University,

[†]Okayama Saiwaicho Memorial Hospital,

[‡]Okayama Saiwaicho Memorial Hospital,

**Okayama University,

^{††}Okayama University,

^{‡‡}Okayama Saiwaicho Memorial Hospital,

[§]Okayama Saiwaicho Memorial Hospital,

[¶]Okayama University,

^{||}Okayama University,

Creation and use of a composite polyurethane-expanded polytetrafluoroethylene graft for hemodialysis access.*

Atsunori Nakao, Masashi Miyazaki, Yoshinari Oka, Hiroaki Matsuda, Masahiro Oishi, Yoshiaki Kokumai, Keiichi Kunitomo, Hiroshi Isozaki, and Noriaki Tanaka

Abstract

The Thoratec (Vectra) polyurethane vascular access graft (TPVA) is among the most recent additions to the list of materials used to construct prosthetic grafts for vascular access during hemodialysis. We give the TPVA very high marks, and recognize the utility of such a graft for use in hemodialysis. However, the strong elasticity of this graft can lead to unexpected complications after suturing. We devised a new surgical method using a TPVA-ePTFE (expanded polytetrafluoroethylene) composite graft, substituting the anastomosis section of the TPVA with a portion of ePTFE graft material, and have been able to overcome most of the TPVA's potential problems. We herein describe the technique.

KEYWORDS: Vectra™ polyurethane graft, expanded polytetrafluoroethylene graft, composite graft

*PMID: 10806530 [PubMed - indexed for MEDLINE]

Copyright (C) OKAYAMA UNIVERSITY MEDICAL SCHOOL

Brief Note

Creation and Use of a Composite Polyurethane-Expanded Polytetrafluoroethylene Graft for Hemodialysis Access

Atsunori NAKAO^{ab*}, Masashi MIYAZAKI^a, Yoshinari OKA^a, Hiroaki MATSUDA^b, Masahiro OISHI^b, Yoshiaki KOKUMAI^a, Keiichi KUNITOMO^a, Hiroshi ISOZAKI^b and Noriaki TANAKA^b

^aDepartment of Surgery, Okayama Saiwaicho Memorial Hospital, Okayama 700-0903 and ^bFirst Department of Surgery, Okayama University Medical School, Okayama 700-8558, Japan

The Thoratec (Vectra™) polyurethane vascular access graft (TPVA) is among the most recent additions to the list of materials used to construct prosthetic grafts for vascular access during hemodialysis. We give the TPVA very high marks, and recognize the utility of such a graft for use in hemodialysis. However, the strong elasticity of this graft can lead to unexpected complications after suturing. We devised a new surgical method using a TPVA-ePTFE (expanded polytetrafluoroethylene) composite graft, substituting the anastomosis section of the TPVA with a portion of ePTFE graft material, and have been able to overcome most of the TPVA's potential problems. We herein describe the technique.

Key words: Vectra™ polyurethane graft, expanded polytetrafluoroethylene graft, composite graft

Many attempts have been made to successfully place an autogenous arterio-venous (A-V) fistula during the performance of hemodialysis as a treatment option for patients suffering from chronic renal failure. However, a recognizable and growing patient cohort exists in which A-V fistula creation is not feasible for a variety of factors. Further, the need for a prosthetic device that can be accessed early is important in the treatment of an increasing number of patients presenting for hemodialysis. Expanded polytetrafluoroethylene (ePTFE) grafts have been used frequently to establish blood access for patients having no suitable arteries and veins with which to create

A-V fistulas. Although ePTFE grafts are seen as a major advance in the treatment of hemodialysis patients, ePTFE could not be called ideal for blood access (1). The Thoratec polyurethane vascular access graft (Vectra™, Thoratec Laboratories Co., Pleasanton, CA, USA) is among the most recent additions to the list of materials used to construct prosthetic grafts for hemodialysis vascular access (2). The Thoratec polyurethane vascular access graft (TPVA) consists of a polyetherurethaneurea blended with silicone and reinforced by spiral polyester fibers. This construction allows the TPVA its kink resistance, durability, and self-sealing properties. The advantages of the TPVA over the ePTFE graft are its quick hemostasis at the anastomotic suture line and better sealability of punctures, in addition to the prevention of perigraft edema and the formation of seromas, which are often observed in patients in which ePTFE grafts are implanted (3). We have found that the elasticity which characterizes the TPVA and helps prevent stenosis due to radial compression by the surrounding tissue is also the cause of some negative effects unique to the TPVA. As a way of overcoming this problem, we devised a new surgical method using a TPVA-ePTFE composite graft, substituting the venous anastomosis section of the TPVA with a portion of ePTFE graft material, and favorable results have been achieved. This technique is described in the following.

* To whom correspondence should be addressed.

Patients and Methods

Between February 1998 and July 1999, we used the TPVA in 22 patients with chronic renal failure and who had no suitable vessels to create an autogenous A-V fistula. Among these, occlusion occurred in 4 patients shortly (between 2 weeks and 6 months) following implantation of the TPVA. Upon exposing the anastomosis area to perform clot removal, the TPVA was found to have caused a kink in the native vein by pulling it upward at the end-to-side anastomosis (Fig. 1). Because we found no other reason for this occlusion, we assume that it was a result of outflow blockage in this kinked area. The TPVA is extremely pliable and is thus susceptible to kinking in certain cases. As a way of overcoming this problem, we devised a new surgical method using a

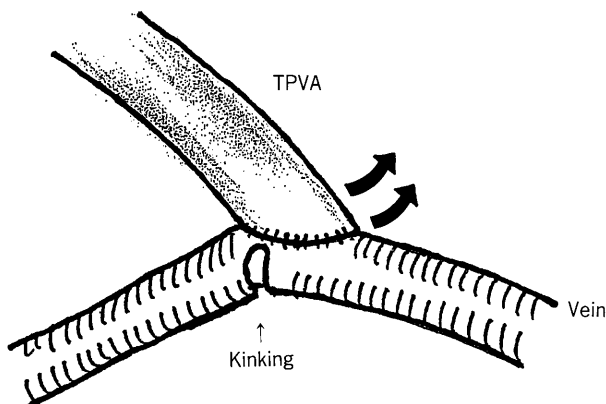


Fig. 1 The problem regarding the Thoratec polyurethane vascular access graft (TPVA) is shown. The graft elasticity of TPVA caused a kink in the native vein by pulling it upward at the end-to-side anastomosis. The outflow blockage from this kinked area consequently led to occlusion.

TPVA-ePTFE composite graft. We performed this procedure in 6 patients including the aforementioned 4 patients and in 2 new patients who presented tight angles of the graft-vessel anastomosis. The clinical data of these 6 patients are shown in Table 1. The backgrounds of these 6 patients, including the cause of hemodialysis, the condition of hemodialysis and arteriosclerosis, and the diameter of the vein were not significantly different from other cases implanted with TPVAs. Data were expressed as the mean standard deviation (SD), and analyzed using the unpaired Student's *t*-test. Statistical difference was considered significant if $P < 0.05$.

The procedure is simple. We implant the TPVA in the forearm, upper arm, or femoral lesion. The artery and vein are carefully dissected. Initially, a 6 mm ePTFE graft is anastomosed to the native artery in the end-to-side fashion. The TPVA is then anastomosed to the ePTFE in the end-to-end fashion. Following this, TPVA is placed in the subcutaneous tunnel through the use of a sheathed tunneling device, necessary to place the TPVA in the correct position. A 6 mm ePTFE graft is then anastomosed to the native vein in a similar fashion and to the TPVA on the other end. The anastomosis between the ePTFE and TPVA material is performed using 6-0 prolene continuous suturing technique (Fig. 2).

Results

We performed this procedure in 6 patients including the aforementioned 4 patients and 2 new patients who presented tight angles of the graft-vessel anastomosis. The grafts were first cannulated for hemodialysis at a median of 2.5 days, with a range of 1 to 4 days. The 8 cases in which the only TPVA grafts were implanted were chosen at random and were compared with those in whom the composite grafts were implanted. (Table 2).

Table 1 Background of the cases implanted the composite graft

Patient	Age (years)	Sex	Cause of HD	Lesion of implantation	Diameter of the vein	Arteriosclerosis	Reason for use of the composite graft
1	48	F	DM	Forearm	5 mm	Moderate	Kinking of the vein
2	55	M	CGN	Forearm	6 mm	Moderate	Kinking of the vein
3	68	M	CGN	Forearm	5 mm	Severe	Kinking of the TPVA
4	49	F	CGN	Forearm	5 mm	Severe	Kinking of the vein
5	56	F	DM	Femoral	7 mm	Moderate	Tight angle of the anastomosis
6	48	F	DM	Femoral	8 mm	Slight	Tight angle of the anastomosis

HD, hemodialysis; DM, diabetes mellitus; CGN, chronic glomerulonephritis.
TPVA, see legend to Fig. 1.

There was no significant difference in procedure time, blood loss, period between surgery and hemodialysis or post-operative complications between the TPVA group and the composite graft group. Within the limited term of the study, all of the transplanted grafts have been patent without occlusion for 3 to 15 months. No kinking was found on both TPVA itself and the anastomosis between

the TPVA and ePTFE materials.

Discussion

We give the TPVA very high marks, and recognize the utility of such a graft for hemodialysis. However, the strong elasticity of this graft can lead to unexpected complications after suturing, and extra precaution in regard to graft-vessel angle must be taken in positioning this graft. Additionally, the TPVA's elasticity can result in enough force to pull up on a native vessel which could lead to flow problems. Particularly when the TPVA is anastomosed with deep native veins, the vein must be more fully exposed and the graft-vessel anastomosis angle tighter, which can create a greater tendency toward pulling upward on the vein and causing it to kink. Another area to note is the extremely high surface friction between the wall of the TPVA and surrounding tissue. Once the TPVA is implanted, the tissue fixes the graft strongly in place. This resistance does lessen some several months after implantation, at which time the TPVA will 'relax' to its own position and have a tendency to contort and wrinkle slightly, particularly around the anastomosis area. However, when it became necessary to remove the TPVA (for reasons such as infection, graft loss, etc.), we found comparatively minimal tissue adhesion, certainly much less than the adhesion associated with ePTFE. Once a portion of the TPVA is separated from the surrounding tissue, it can be removed relatively easily. This may well reflect the differing biocompatibility of each graft material, which also can gradually develop a kink around the anastomosis area.

We devised a new surgical method using a TPVA-ePTFE composite graft, substituting the anastomosis section of the TPVA with a portion of ePTFE graft material, and have been able to overcome most of the TPVA's potential problems. The utilization of such a 'composite-graft' method has also been reported by Nakagawa *et al.* (4), in which ePTFE was first anas-

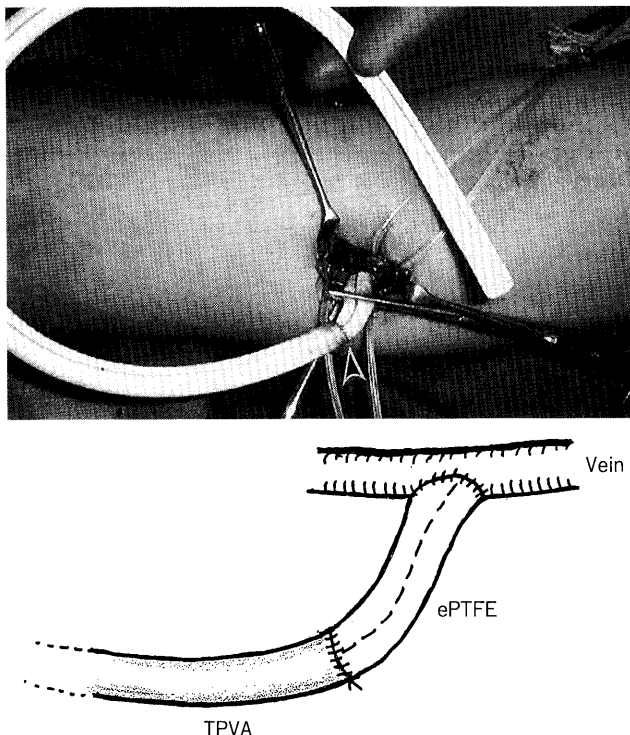


Fig. 2 The composite graft using TPVA and expanded polytetrafluoroethylene (ePTFE).

The artery and vein are carefully dissected. Initially, the ePTFE graft is anastomosed to the native artery in the end-to-side fashion. The TPVA is then anastomosed to the ePTFE in the end-to-end fashion. After the TPVA is placed in the subcutaneous tunnel, the ePTFE graft is anastomosed to the native vein in a similar procedure and to the TPVA on the other end.

TPVA, see legend to Fig. 1.

Table 2 Comparison between TPVA and the composite graft

	Number	Procedure time (min)	Blood loss	Period between surgery and HD (days)	Complication
TPVA	8	75.6 ± 12.9	Slight	1.9 ± 0.83	No
Composite graft	6	83.3 ± 8.2	Slight	2.5 ± 1.8	No

HD; TPVA, see legends to Fig. 1 and Table 1.

tomosed to a TPVA in an end-to-end configuration and was then implanted as a single graft. Through our technically simpler method, however, in which we first attach the TPVA, we expect to produce better outcomes due to the alleviation of stress on the native vessel.

We reported that the character of the TPVA material caused a kink in the native vein by pulling it upward, creating outflow blockage from this kinked area. In this study we aimed to focus more closely on a unique problem which we have rarely experienced, a complication induced by graft elasticity, as well as our technique which has been shown useful in overcoming this problem. We believe this method, substituting the anastomosis section of the TPVA with an ePTFE graft, has harmonized the strengths and weaknesses of each graft material. In the future we hope to further investigate this method as well

as its long-term patency rates in a larger patient cohort.

References

1. Ota K, Sasaki Y, Nakagawa Y and Teraoka S: A completely new poly (ether-urethane) graft ideal for hemodialysis blood access. *Am Soc Artif Intern Organs Trans* (1987) **33**, 129-135.
2. Allen RD, Yuill E, Nankivell BJ and Francis DM: Australian multi-centre evaluation of a new polyurethane vascular access graft. *Aust NZ J Surg* (1996) **66**, 738-742.
3. Ota K, Nakagawa Y, Kitano Y, Oshima T and Teraoka S: Clinical application of modified polyurethane graft to blood access. *Artif Organs* (1991) **15**, 449-453.
4. Nakagawa Y, Nakamura R and Yasumura H: A technique to prevent kinking in polyurethane grafts. *J Jpn Soc Dial Ther* (1999) **32**, 784 (in Japanese).

Received October 1, 1999; accepted January 7, 2000.