

Contrast-enhanced Computed Tomography Screening Is Effective for Detecting Venous Thromboembolism not Prevented by Prophylaxis after Total Knee Arthroplasty

Yukimasa Okada^{a*}, Takayuki Furumatsu^a, Shinichi Miyazawa^a, Takaaki Tanaka^a,
Masataka Fujii^a, Toshifumi Ozaki^a, and Nobuhiro Abe^{a,b}

^aDepartment of Orthopaedic Surgery, Okayama University Graduate School of Medicine,
Dentistry and Pharmaceutical Sciences, Okayama 700-8558, Japan and

^bDepartment of Orthopaedic Surgery and Sport Medicine, Kawasaki Hospital, Kawasaki Medical School, Okayama 700-0821, Japan

Venous thromboembolism (VTE) is a potential complication occurring after total knee arthroplasty (TKA). We investigated the incidence of VTE after TKA using contrast-enhanced computed tomography (CT), and assessed the efficacy of VTE prophylaxis (fondaparinux and enoxaparin). At our hospital, 189 patients (225 knees) underwent TKA between April 2007 and October 2011. The 225 knees were divided into a control group with no VTE prophylaxis (31 cases), a fondaparinux group (107 cases), and an enoxaparin group (87 cases). Contrast-enhanced CT screening for VTE was performed in all cases on day 5 or 6 after TKA. D-dimer levels were measured on day 5 after TKA, and were significantly lower in the fondaparinux (9.8 ± 3.8) and enoxaparin groups (9.4 ± 4.9) than in the control group (15.6 ± 9.8) ($p < 0.001$). However, no statistically significant difference in the incidence of VTE was observed among the groups (control, 61.3%; fondaparinux, 49.5%; enoxaparin, 50.6%). Prophylaxis was not effective for the prevention of VTE as detected by contrast-enhanced CT after TKA. CT should be performed after TKA, even when VTE prophylaxis is used.

Key words: venous thromboembolism, contrast-enhanced computed tomography, total knee arthroplasty, fondaparinux, enoxaparin

Venous thromboembolisms (VTEs) are serious potential complications after total knee arthroplasty (TKA) [1]. The incidence of symptomatic VTEs is 0.5–1.0%, even when heparin or other anticoagulants are used [2–4]. Symptomatic pulmonary embolisms (PEs) develop in 0.41%; PEs are lethal in 0.15% of TKA patients.

Use of the selective clotting factor Xa inhibitor, fondaparinux, as a VTE prophylactic agent after

TKA has been permitted in Japan since 2007. The low-molecular-weight heparin, enoxaparin, was subsequently approved in 2008. Several published reports have evaluated the efficacy of these agents [5–9]. However, these studies used venography or lower extremity vascular ultrasound for VTE screening; detailed assessments of contrast-enhanced CT have not been published.

The aim of this study was to investigate the incidence of VTE after TKA using contrast-enhanced CT,

and to assess the efficacy of VTE prophylaxis.

Materials and Methods

All patients provided preoperative written consent before the commencement of the study. The study design was approved by the ethics committee of Okayama University Graduate School of Medicine, Dentistry and Pharmaceutical Sciences under approval number 2144. The subjects of this retrospective study were 214 patients (278 knees) who underwent TKA at our hospital between April 2007 and November 2012.

Patients were excluded from the study for any of the following reasons: re-replacement, coagulation disorders, preoperative anticoagulant therapy, past history of VTE, past history of respiratory distress, chest pain, syncope, or hypotension, lower extremity swelling or flaring, impairment of hepatic or renal function, allergy to contrast agents, preoperative D-dimer values above the normal range, and lack of consent for tests. After screening for the exclusion criteria, 189 patients (225 knees) were included in the study.

The 225 subject knees were divided into the following 4 groups. Between April 2007 and October 2008, the control knees ($n = 31$) were treated without DVT prophylactic agents; only elastic stockings and intermittent pneumatic compression devices were used. The fondaparinux group (107 knees), treated between July 2007 and October 2009, received fondaparinux (2.5 mg/day), and the enoxaparin group (87 knees), treated between November 2009 and October 2011, received enoxaparin (2,000–4,000 IU/day). In all cases, the use of prophylactic agents began 24–36 hours after TKA, the recommended interval in Japan.

Immediately after surgery, all patients wore elastic stockings and used an intermittent pneumatic compression device. By the second post-surgical day, all patients began ambulation and gait training. D-dimer levels were measured on day 5 after TKA. In patients undergoing bilateral TKA, surgery was performed on one knee followed by the second procedure, at least 3 months later.

Contrast-enhanced CT images were obtained from the pulmonary apex to the foot in all cases, and the incidences of symptomatic PE, asymptomatic PE, and DVT were compared. Contrast-enhanced CT was

performed 5–6 days after surgery, using a 64-row multi-slice CT (Aquilion 64[®]; Toshiba Medical Systems, Okayama, Japan). The contrast agent, Iopamiron[®] (Bracco, Milan, Italy), was injected into an upper-extremity vein (100 ml, 4 ml/sec). During the arterial phase, for 22 sec after injection, imaging was performed from the pulmonary apex to the costophrenic angle. During the venous phase, 300 sec after injection of contrast agent, imaging was performed from the diaphragm to the foot. All images were acquired as 2-mm horizontal axial sections, from which coronal and sagittal sections were reconstructed. A radiologist examined the images to determine the presence of VTEs.

When a thrombosis was found in the pulmonary artery or its segmental branches, the patient's symptoms and physical findings were confirmed, and an echocardiogram was performed by a cardiovascular specialist. Patients without specific symptoms, physical findings, or echocardiographic abnormalities were considered to have asymptomatic PEs. Patients who had symptoms such as tachycardia, hypoxemia, or chest pain or who showed right atrial overload on echocardiography, were considered to have symptomatic PEs. Patients who presented with thrombosis in their lower extremities were considered to have DVTs.

SPSS version 22.0 for Windows (IBM Japan, Ltd., Tokyo, Japan) was used for all statistical analyses. The normality of continuous variables was confirmed using the Shapiro-Wilk test. Normally distributed, continuous variables were compared using the Tukey-Kramer test, whereas non-normally distributed continuous variables were compared using the Steel-Dwass test. Fisher's exact test was used to compare percentages, and Holm's method was used to control multiplicity. The level of statistical significance was set at $p < 0.05$.

Results

There were no statistically significant differences among the groups with regard to age, gender, diagnosis, body mass index, duration of surgery, duration of post-surgical tourniquet use, or method of anesthesia (Table 1).

D-dimer levels on day 5 after TKA were significantly lower in the fondaparinux and enoxaparin groups than in the control group ($p < 0.001$).

The incidence of symptomatic PE was lower in the enoxaparin group than in the control group, but the difference was not statistically significant ($p = 0.067$). High rates of asymptomatic PE (Fig. 1) and DVT were observed in all groups, but the differences were not statistically significant (Table 2). Patients diagnosed with symptomatic PE presented only mild clinical symptoms and physical findings. As a result, PE was not suspected based on clinical findings alone. The diagnosis of symptomatic PE was confirmed by the presence of thrombosis in the pulmonary artery using contrast-enhanced CT (Fig. 2).

Discussion

In the present study, we used contrast-enhanced

CT to examine the incidence of VTE after TKA. Our results indicated that VTE prophylaxis was effective in lowering D-dimer levels on day 5 after TKA, but did not affect the incidence of VTE as detected by contrast-enhanced CT. CT screening should be performed after TKA, even when VTE prophylaxis is used, with conversion to anticoagulant therapy if the CT is positive for VTE [10].

In previous studies, the incidence of VTE was correlated with D-dimer level, and the incidence after TKA was reduced by using prophylactic medication, such as fondaparinux and enoxaparin [7–9, 11]. However, in these studies, VTE screening was performed with venography or lower extremity vascular ultrasound. In our study using contrast-enhanced CT, with a very high detection level, the incidence of VTE

Table 1 Patient data

		Control (n = 31)	Fondaparinux (n = 107)	Enoxaparin (n = 87)
Age in years	Median [IQR]	73 [64–76]	73 [64–76]	73 [62–76]
Gender, n (%)	Male	6 (19.4)	21 (19.6)	16 (18.4)
	Female	25 (80.6)	86 (80.4)	71 (81.6)
Diagnosis, n (%)	Osteoarthritis	21 (67.7)	78 (72.9)	56 (64.4)
	Rheumatoid arthritis	8 (25.8)	22 (20.6)	27 (31.0)
	Osteonecrosis	2 (6.5)	7 (6.5)	4 (4.6)
Bilateral TKA, n (%)		5 (16.1)	17 (15.9)	12 (13.8)
Body mass index (kg/m ²)	Mean ± SD	24.5 ± 3.6	24.4 ± 4.1	25.6 ± 4.3
Duration of surgery (min)	Median [IQR]	170 [150–195]	168 [140–195]	175 [155–195]
Duration of tourniquet use (min)	Median [IQR]	102 [75–130]	100 [85–130]	90 [90–100]
Method of anesthesia, n (%)	General anesthesia	31 (100.0)	104 (97.2)	87 (100.0)
	Spinal anesthesia	0 (0)	3 (2.8)	0 (0)

No statistically significant difference was observed among the groups. IQR, inter-quartile range [first quartile to third quartile].

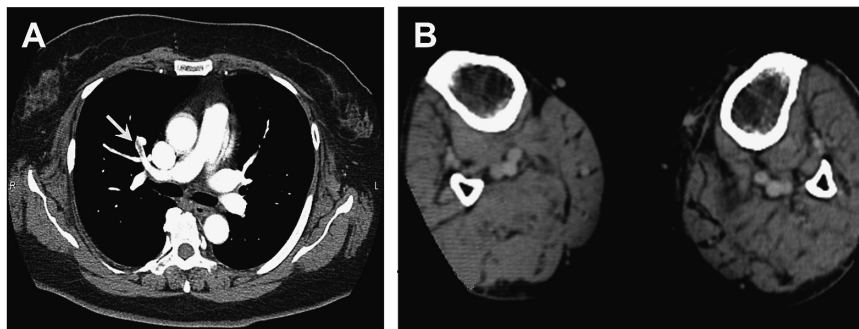


Fig. 1 A 57-year-old woman underwent initial total knee arthroplasty due to right knee osteoarthritis. Contrast-enhanced computed tomography was performed 6 days after surgery. **A**, Thrombosis was detected in the segmental branches of the right pulmonary artery (arrow); **B**, No thrombosis was evident in the femur or veins of the lower extremity.

Table 2 Incidence of deep vein thromboses (DVTs) and pulmonary embolisms (PEs)

	Control (n = 31)	Fondaparinux (n = 107)	Enoxaparin (n = 87)
D-dimer on day 5 after TKA (ug/ml), mean \pm SD	15.6 \pm 9.8	9.8 \pm 3.8*	9.4 \pm 4.9*
VTE, n (%)	19 (61.3)	53 (49.5)	44 (50.6)
Symptomatic PE, n (%)	2 (6.5)	3 (2.8)	0 (0)
Asymptomatic PE, n (%)	6 (19.4)	25 (23.4)	16 (18.4)
DVT, n (%)	11 (35.5)	25 (23.4)	28 (32.2)

* $p < 0.001$ vs. control group.

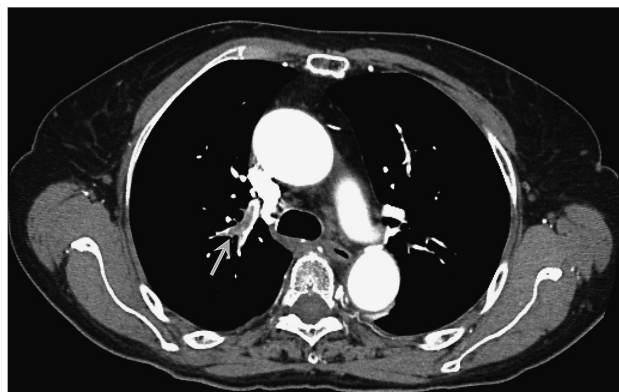


Fig. 2 A 77-year-old woman underwent initial total knee arthroplasty due to right knee osteoarthritis. Contrast-enhanced computed tomography was performed 6 days after surgery. Thrombosis was detected in the segmental branches of the right pulmonary artery (arrow). Mild hypoxemia was observed on the first day after surgery, and follow-up observation was conducted during oxygen administration. Right atrial overload was noted on an echocardiogram obtained by a cardiovascular specialist, consistent with a diagnosis of symptomatic PE.

in the enoxaparin and fondaparinux groups was not significantly different from that in the control group.

VTE screening methods include venography, lower extremity vascular ultrasound, pulmonary scintigraphy, pulmonary arteriography, and contrast-enhanced computed tomography (CT). Although venography and lower extremity vascular ultrasound can detect deep venous thromboses (DVTs) in the lower extremities, pulmonary thromboses pose a diagnostic problem.

Conversely, contrast-enhanced CT screening is highly sensitive (100%) and specific (96.6%), making it a useful diagnostic tool [12]. Watanabe *et al.* performed contrast-enhanced CT after TKA and found asymptomatic PEs in 15.6% of patients and DVTs in 46.9% [13]. Gandhi *et al.* reported post-TKA, contrast-enhanced CT-detected asymptomatic PE in

40.7% [14].

The incidence of symptomatic PEs after TKAs, in the absence of prophylaxis, is approximately 1.0% [15, 16]. In the present study, the incidence of symptomatic PEs in the control and fondaparinux groups was 6.5%, higher than that in other reports, possibly because contrast-enhanced CT enabled a higher detection rate for symptomatic PEs. Parvizi *et al.* reported an incidence of 0.21% for symptomatic PEs, diagnosed by lung perfusion scintigraphy. However, when contrast-enhanced CT was used, the incidence increased to 1.72% [4]. The use of contrast-enhanced CT in our study may have had a similar effect on the incidence of PEs because of the inclusion of asymptomatic PEs, which are normally difficult to diagnose. PE symptoms include transient tachycardia, hypoxemia, and chest pain [17]. However, the incidence of hypoxemia after TKA ranges from 4% to 42% when causes other than PE are included. In addition, respiratory distress is uncommon in isolated subsegmental PE [18]. Therefore, determination of whether hypoxemia and other symptoms that occur after TKA are due to PE is difficult, complicating the differential diagnosis of symptomatic PE [19, 20].

The reported incidence of asymptomatic PE after TKA ranges between 0% and 57% [13, 14, 21, 22]. Kim *et al.* found no cases of PE among 227 TKA patients using lung perfusion scintigraphy [21]. However, Gandhi *et al.* screened 27 patients after TKA using contrast-enhanced CT, and found asymptomatic PE in 41% of them [14]. These results show that the incidence of asymptomatic PE varies greatly, according to the screening method. In the present study, the incidence of asymptomatic PE was 19.4%. Although this figure is higher than that reported following lung perfusion scintigraphy, it is lower than that for other contrast-enhanced CT protocols. This

may have been due to our use of 2-mm slices for imaging, as well as our initiation of DVT prophylaxis at an early stage after surgery.

The absence of VTE screening before surgery is a possible limitation of the present study. However, because D-dimers before surgery were within the normal range in all patients, the possibility that a patient had a pre-surgical VTE was extremely low [13]. We speculate that the majority of cases of asymptomatic PEs detected in the present study developed after surgery.

In conclusion, we performed contrast-enhanced CT screening for VTE after TKA, and assessed the efficacy of contrast-enhanced CT and the VTE prophylactic agents fondaparinux and enoxaparin. Neither agent had a prophylactic effect on VTE detected on contrast-enhanced CT. CT screening should be performed after TKA, even when VTE prophylaxis is used; if the CT is positive for VTE, medication should be converted to anticoagulant therapy.

Acknowledgments. This study was supported by grants from the Japanese Foundation for Research and Promotion of Endoscopy and the JSPS Fujita Memorial Fund for Medical Research.

References

- Berend KR and Lombardi AV Jr: Multimodal venous thromboembolic disease prevention for patients undergoing primary or revision total joint arthroplasty: the role of aspirin. *Am J Orthop (Belle Mead NJ)* (2006) 35: 24–29.
- Howie CH, Hughes H and Watts AC: Venous thromboembolism associated with hip and knee replacement over a ten-year period: a population-based study. *J Bone Joint Surg Br* (2005) 87: 1675–1680.
- Soochoo NF, Zingmond DS, Lieberman JR and Ko CY: Primary total knee arthroplasty in California 1991 to 2001: does hospital volume affect outcomes? *J Arthroplasty* (2006) 21: 199–205.
- Parvizi J, Smith EB, Pulido L, Mamelak J, Morrison WB, Purtill JJ and Rothman RH: The rise in the incidence of pulmonary embolus after joint arthroplasty: is modern imaging to blame? *Clin Orthop Relat Res* (2007) 463: 107–113.
- Sasaki S, Miyakoshi N, Matsuura H, Saitoh H, Kudoh D and Shimada Y: Prospective randomized controlled trial on the effect of fondaparinux sodium for prevention of venous thromboembolism after hip fracture surgery. *J Orthop Sci* (2009) 14: 491–496.
- Fuji T, Ochi T, Niwa S and Fujita S: Prevention of postoperative venous thromboembolism in Japanese patients undergoing total hip or knee arthroplasty: two randomized, double-blind, placebo-controlled studies with three dosage regimens of enoxaparin. *J Orthop Sci* (2008) 13: 442–451.
- Hosaka K, Saito S, Ishii T, Sumino T, Ryu K, Suzuki G, Suzuki T and Tokuhashi Y: Safety of fondaparinux versus enoxaparin after TKA in Japanese patients: *Orthopedics* (2013) 36: e428–e433.
- Fuji T, Ochi T, Niwa S and Fujita S: Prevention of postoperative venous thromboembolism in Japanese patients undergoing total hip or knee arthroplasty: two randomized, double-blind, placebo-controlled studies with three dosage regimens of enoxaparin. *J Orthop Sci* (2008) 13: 442–451.
- Sadaki S, Miyakoshi N, Matsuura H, Saitoh H, Kudoh D and Shimada Y: Prospective randomized controlled trial on the effect of fondaparinux sodium for prevention of venous thromboembolism after hip fracture surgery. *J Orthop Sci* (2009) 14: 491–496.
- JCS Joint Working Group: Guidelines for the diagnosis, treatment and prevention of pulmonary thromboembolism and deep vein thrombosis (JCS 2009). *Circ J* (2011) 75: 1258–1281.
- Shiota N, Sato T, Nishida K, Matsuo M, Takahara Y, Mitani S, Murakami T and Inoue H: Changes in LPIA D-dimer levels after total hip or knee arthroplasty relevant to deep vein thrombosis diagnosed by bilateral ascending venography. *J Orthop Sci* (2002) 7: 444–450.
- Begemann PG, Bonacker M, Kemper J, Guthoff AE, Hahn KE, Steiner P and Adam G: Evaluation of the deep venous system in patients with suspected pulmonary embolism with multi-detector CT: a prospective study in comparison to Doppler sonography. *J Comput Assist Tomogr* (2003) 27: 399–409.
- Watanabe H, Sekiya H, Kariya Y, Hoshino Y, Sugimoto H and Hayasaka S: The incidence of venous thromboembolism before and after total knee arthroplasty using 16-row multidetector computed tomography. *J Arthroplasty* (2011) 26: 1488–1493.
- Gandhi R, Salonen D, Geerts WH, Khanna M, McSweeney S and Mahomed NN: A pilot study of computed tomography-detected asymptomatic pulmonary filling defects after hip and knee arthroplasties. *J Arthroplasty* (2012) 27: 730–735.
- Geerts WH, Pineo GF, Heit JA, Bergqvist D, Lassen MR, Colwell CW and Ray JG: Prevention of venous thromboembolism: the Seventh ACCP Conference on Antithrombotic and Thrombolytic Therapy. *Chest* (2004) 126 (Suppl 3): 338S–400S.
- Fujita S, Hirota S, Oda T, Kato Y, Tsukamoto Y and Fuji T: Deep venous thrombosis after total hip or total knee arthroplasty in patients in Japan. *Clin Orthop Relat Res* (2000) 375: 168–174.
- Stein PD, Fowler SE, Goodman LR, Gottschalk A, Hales CA, Hull RD, LEEPER KV Jr, Popovich J Jr, Quinn DA, Sos TA, Sostman HD, Tapson VF, Wakefield TW, Weg JG, Woodard PK and PIOPED II Investigators: Multidetector computed tomography for acute pulmonary embolism. *N Engl J Med* (2006) 354: 2317–2327.
- Le Gal G, Righini M, Parent F, van Strijen M and Couturaud F: Diagnosis and management of subsegmental pulmonary embolism. *J Thromb Haemost* (2006) 4: 724–731.
- Kerr J and Linkins LA: High incidence of in-hospital pulmonary embolism following joint arthroplasty with dalteparin prophylaxis. *Thromb Haemost* (2010) 103: 123–128.
- Miniati M, Prediletto R, Formichi B, Marini C, Di Ricco G, Tonelli L, Allescia G and Pistolesi M: Accuracy of clinical assessment in the diagnosis of pulmonary embolism. *Am J Respir Crit Care Med* (1999) 159: 864–871.
- Kim YH, Oh SH and Kim JS: Incidence and natural history of deep-vein thrombosis after total hip arthroplasty. A prospective and randomised clinical study. *J Bone Joint Surg Br* (2003) 85: 661–665.
- Haas SB, Tribus CB, Insall JN, Becker MW and Windsor RE: The significance of calf thrombi after total knee arthroplasty. *J Bone Joint Surg Br* (1992) 74: 799–802.